THE THROMBOSIS INTEREST GROUP OF CANADA
. . . dedicated to furthering education and research www.tigc.org

Clinical Guide - Suspected PE (Reviewed 2006)

Principal Developer: B. Geerts
Secondary Developers: C. Demers, C. Kearon

Background

- Investigation of patients with suspected pulmonary emboli (PE) remains problematic and controversial - there are several ways to "rule in" and "rule out" the diagnosis (or, more importantly, to make a decision about anticoagulation or not)
- At least 70% of patients with suspected PE don't have it
- PE is nearly always a complication of (proximal) DVT

Presentations of PE:

- **Shortness of breath**
- **Chest pain (usually pleuritic)**
- **Hemoptysis**
- **Pre-syncope or syncope**
- **Shock**
- **Hypoxemia**
- **Arrhythmia especially atrial fibrillation**
- **Fever**
- **Right heart failure**
- **Pulmonary hypertension**
- **Sudden death**

Clinical Priorities in the Investigation of Patients with Suspected PE

Not every PE can (or needs to) be diagnosed. The clinical situations priorities in the investigation of patients with suspected PE include:

1. Diagnosis of extensive PE
2. Diagnosis of PE in patients with severe symptoms and/or poor cardiopulmonary reserve
3. Diagnosis of any PE when associated with symptomatic or asymptomatic proximal DVT
4. Diagnosis in patients presenting with possible recurrent PE

Tests that are Generally NOT Helpful in the Diagnosis of Possible PE:

1. Arterial blood gases - are usually abnormal in PE but are of little or no diagnostic value in patients with suspected PE since the alternative conditions under consideration are just as likely to produce similar blood gas changes.
2. ECG and CXR - are both frequently abnormal in PE but rarely help to confirm or exclude PE - their greatest value is in the evaluation of alternative diagnostic considerations.

Tests That May be Helpful (but are not diagnostic on their own):

1. Clinical suspicion - Cannot prove or exclude PE but may assist with a decision for further testing. For example, if clinical suspicion strongly disagrees with non-invasive tests, further testing should be considered.
2. D-dimer - Although most patients with PE and DVT have an elevated D-dimer result, D-dimer is also elevated in many other conditions (such as recent injury or surgery, cancer, inflammatory diseases, healthy elderly, etc). Therefore, a positive test result is not helpful. A negative result, using a sensitive D-dimer assay, helps to rule out PE. However, a D-dimer test that has been validated as a diagnostic test for PE must be used, and then it should be used in the same way it was in the original studies (the majority of D-dimer assays in current use are not sensitive enough to be used in the exclusion of PE/DVT on their own).

3. Echocardiogram - Although the echocardiogram is often abnormal in the presence of major PE (and may have prognostic value), it has limited diagnostic value by itself

Ventilation/Perfusion Lung Scanning (V/Q scan)

There are 3 V/Q lung scan patterns:

1. A normal perfusion scan rules out PE.
2. Most patients with a high probability scan (defined as one or more, segmental or larger, perfusion defects with relatively preserved ventilation) have PE and they can generally be treated without further testing.
3. All other lung scan patterns (which, unfortunately, includes 60% of all the scans) are nondiagnostic. These nondiagnostic patterns include 'low probability', 'nonhigh probability', 'intermediate probability', and 'indeterminate probability'. Further testing is required in patients with this V/Q scan pattern.

Advantages of V/Q Lung Scans include:

1. a normal V/Q scan rules out PE
2. the radiation dose is low
3. iodine-based contrast is not used

Limitations of V/Q Lung Scans include:

1. the majority of V/Q scans are nondiagnostic
2. V/Q scans do not help to identify an alternate diagnosis in the large proportion of patients who don't have PE.
3. relatively high cost

CT Pulmonary Angiography (CTPA)
- also sometimes called "spiral CT" or helical CT"

There are 5 CTPA patterns:
1. Definite PE is an unequivocal filling defect seen in a segmental or larger pulmonary artery.
2. No PE is seen and a convincing alternate diagnosis is found. Patients with this CTPA pattern do not require any further investigation for VTE.
3. a) No PE seen on a technically adequate, single detector CTPA but no convincing alternate diagnosis is found. Most patients with this CTPA pattern should have further investigation for VTE (e.g. bilateral ultrasonography of the proximal veins).

b) No PE seen on a technically adequate, multidetector-row CTPA. Most patients with this CTPA pattern do not require any further investigation for VTE.

4. Technically inadequate scans are nondiagnostic and further testing is required.
5. Subsegmental PE should generally be considered nondiagnostic. Further testing is usually required in patients with this CTPA pattern.

- CTPA is rapidly replacing V/Q Lung Scanning.
- In many hospitals, CT venography of the major pelvic and proximal leg veins is obtained as part of the CTPA procedure. However, the accuracy of CT venography has not yet been proven and the additional radiation dose is substantial.

Advantages of CTPA include:

1. ability to directly visualize embol
2. high accuracy for large emboli (segmental or larger)
3. potential to provide the alternate diagnosis in patients without PE

Limitations of CTPA include:

1. filling defects confined to subsegmental vessels are often not diagnostic and patients with this CTPA pattern may be inappropriately anticoagulated without certainty that they even have PE
2. contrast must be given (problematic in patients with renal insufficiency or a history of contrast allergy)
3. substantial radiation dose (equivalent to approximately 500 chest x-rays)

Venous Imaging in Patients with Suspected PE

Since almost all pulmonary emboli arise from DVT, a useful strategy in some patients with suspected PE is to look for the presence of DVT using Duplex ultrasound (DUS).

- If the DUS of the proximal veins is positive, the patient requires treatment (and the treatment of proximal DVT and PE is the same).
- If the DUS is negative, the risk of recurrent PE in the short term is very low.
- Repeating the DUS testing in 5-7 days is a safe strategy in suspected PE with nondiagnostic lung imaging.

Approach to Patients with Suspected PE

1. **Should I start with lung imaging (V/Q scan, CTPA) or with DUS?**

- Consider starting with a DUS if: There are leg symptoms or signs that are compatible with DVT
- There has recently been leg injury or leg surgery
- Pregnancy

2. **If I start with lung imaging, should it be a V/Q scan or CTPA?**

Choose V/Q Scan	**Choose CTPA**
1. Normal CXR	1. Abnormal CXR
2. Patient is otherwise healthy	2. Respiratory disease
3. CTPA is contraindicated (because of contrast allergy or renal failure)	3. Critical care patient
	4. Suspect massive PE

- There are very few indications do both a V/Q scan and a CTPA.

A number of diagnostic algorithms for the investigation of patients with suspected PE have been studied. Three algorithms are presented here

- Figure 1: is based on Imaging Tests Alone
- Figure 2: incorporates a formal clinical probability assessment and a sensitive D-dimer assay along with V/Q lung scanning
- Figure 3: incorporates a formal clinical probability assessment and a sensitive D-dimer assay along with CTPA
- For patients who have PE excluded by one of these algorithms, the chance of DVT/PE in the next 3 months is less than 1%.

Figure 1: Investigation of Suspected PE Based on Imaging Tests Alone

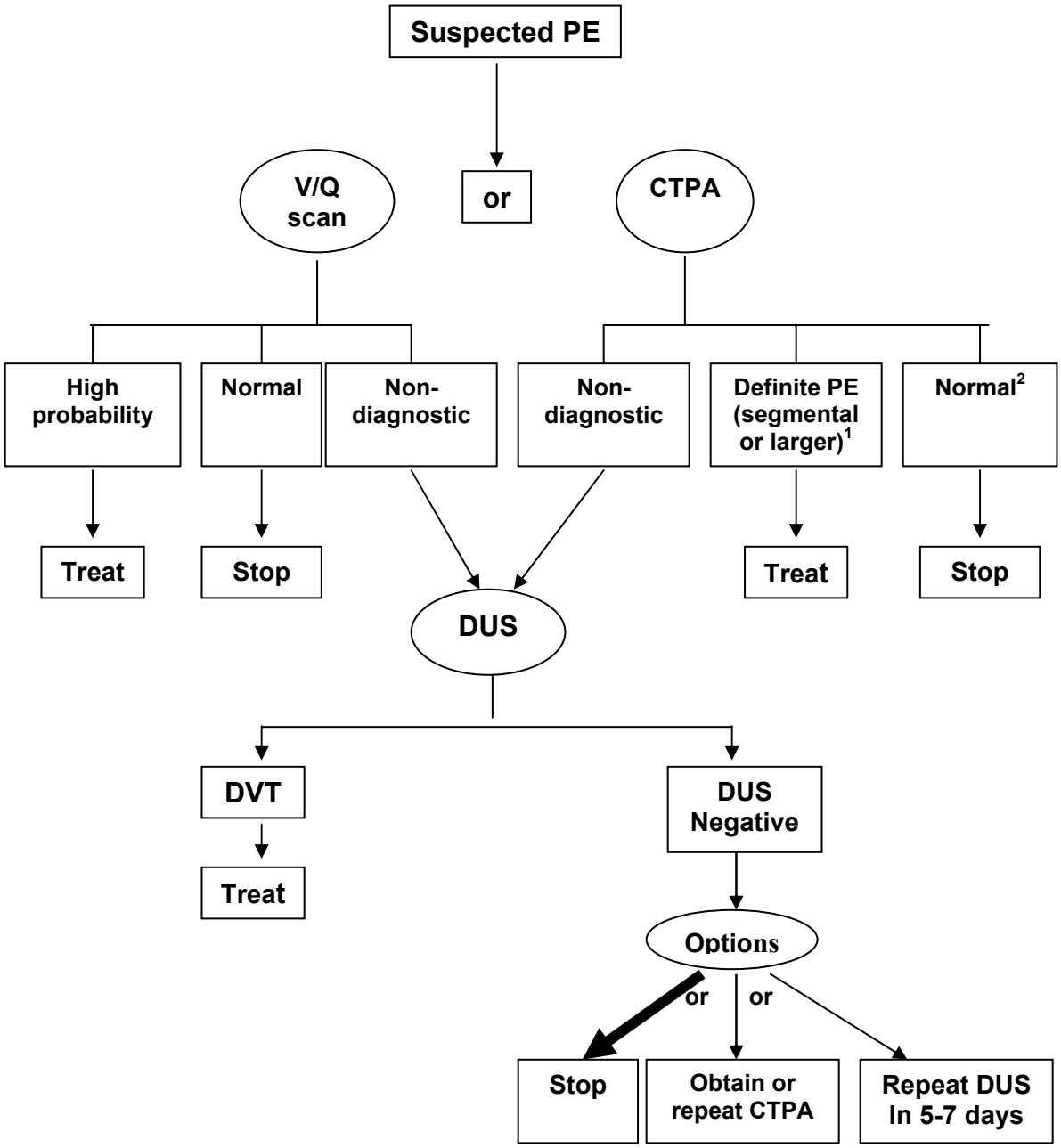

1 A subsegmental filling defect on CTPA should generally be considered nondiagnostic
2 With a normal CTPA and a high clinical suspicion for PE, further testing should be considered

Figure 2: Investigation of Suspected PE Using Clinical Probability Assessment, Sensitive D-dimer, and V/Q Lung Scanning

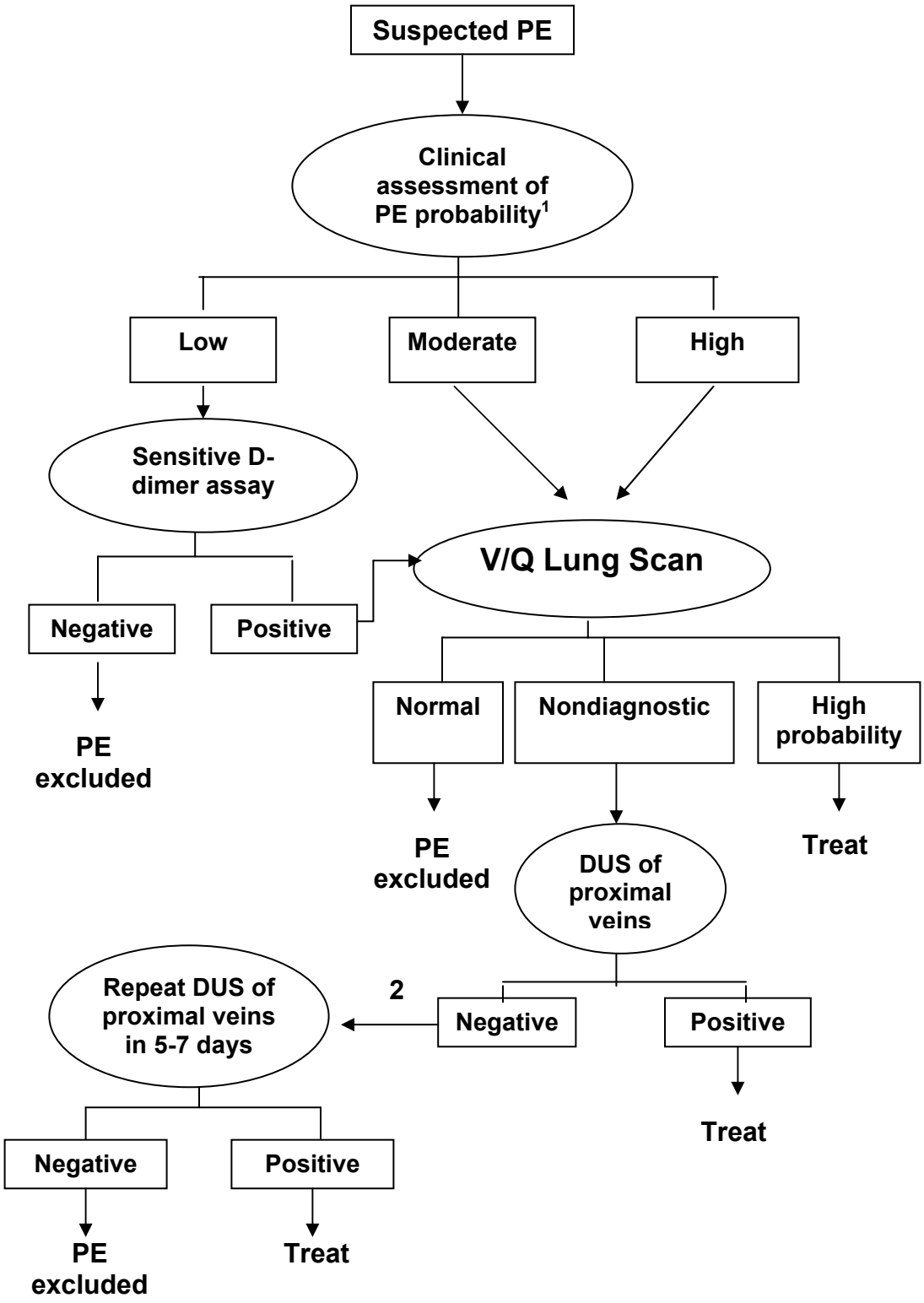

1 See validated probability assessment that follows after Figure 3
2 If a sensitive D-dimer test is negative, serial DUS testing is not required

Figure 3: Investigation of Suspected PE Using Clinical Probability Assessment, Sensitive D-dimer, and CTPA

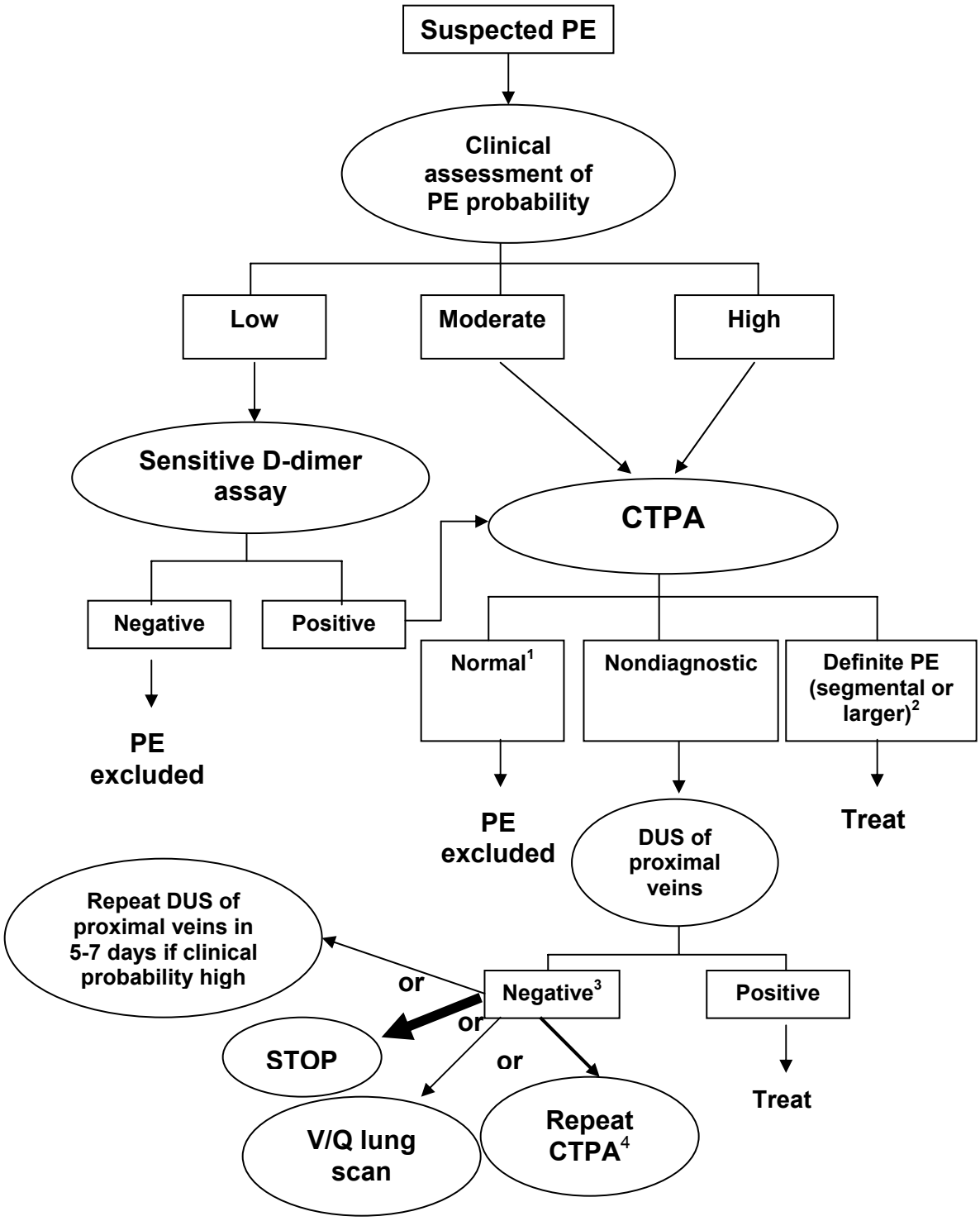

1 With a normal CTPA and a high clinical suspicion for PE, or a normal CTPA performed on a single detector scanner, further testing should be considered
2 A subsegmental filling defect on CTPA should generally be considered nondiagnostic
3 If a sensitive D-dimer test is negative, further testing is not required
4 If the initial CTPA is nondiagnostic for technical reasons, repeating it might resolve the uncertainty.

Clinical Probability Assessment for Pulmonary Embolism

Variable	Points
• Clinical symptoms and signs of DVT (leg swelling and pain with palpation)	3.0
• No alternative diagnosis is more likely than PE	3.0
• Heart rate > 100 beats/min	1.5
• Immobilization or surgery previous 4 weeks	1.5
• Previous DVT/PE	1.5
• Hemoptysis	1.0
• Malignancy (treated within previous 6 mos or palliative)	1.0
Total points	_____

Clinical pretest probability of PE:	Total Points
High	>6
Moderate	2-6
Low	<2

• Wells PS, et al. Ann Intern Med 2001;135:98

Summary of Management Approaches in Patients with Suspected PE

- **Anticoagulate patients with suspected PE when:**

1. Diagnostic testing will be delayed more than a few hours or large PE is suspected
2. DUS shows proximal DVT
3. V/Q lung scan is “high probability”
4. CTPA shows segmental or larger filling defect
5. CT venography shows definite DVT
6. Pulmonary angiogram is positive
7. There is another indication for anticoagulation (such as atrial fibrillation)

- **Anticoagulation is not needed if:**

1. A low clinical probability of PE combined with a negative sensitive D-dimer assay
2. Perfusion lung scan normal
3. CTPA does not show PE and demonstrates an alternate Dx
4. CTPA does not show PE and there is no proximal DVT on DUS or CTvenography and clinical probability of PE is low or moderate
5. A multidetector-row CTPA is normal
6. Pulmonary angiogram that is normal
7. A nondiagnostic lung scan with normal serial DUS

*** The approach is uncertain (further testing is generally required):**

1. V/Q lung scan is nondiagnostic
2. CTPA is nondiagnostic
3. There is discordance between the clinical probability and the imaging results

References:

1. Kearon C. Diagnosis of pulmonary embolism. CMAJ 2003;168:183-194
2. Roy PM, et al. Systematic review and meta-analysis of strategies for the diagnosis of suspected pulmonary embolism. BMJ 2005;331:259-267
3. Stein PD, et al. D-dimer for the exclusion of acute venous thrombosis and pulmonary embolism: a systematic review. Ann Intern Med 2004;140:589-602
4. Heim SW, et al. D-dimer testing for deep venous thrombosis: a metaanalysis. Clin Chem 2004;50:1136-1147

5. Wells PS, Rodger M. Diagnosis of pulmonary embolism: when is imaging needed? Clin Chest Med 2003;24:13-28
6. Chunilal SD, et al. Does this patient have pulmonary embolism? JAMA 2003;290:2849-2858
7. Perrier A, et al. Multidetector-row computed tomography in suspected pulmonary embolism. NEJM 2005;352:1760-1768
8. Moores LK, et al. Meta-analysis: outcomes in patients with suspected pulmonary embolism managed with computed tomographic pulmonary angiography. Ann Intern Med 2004;141:866-874
9. Perrier A, et al. Diagnosing pulmonary embolism in outpatients with clinical assessment, D-dimer measurement, venous ultrasound, and helical computed tomography: a multicenter management study. Am J Med 2004;116:291-299
10. Kruip MJHA, et al. Diagnostic strategies for excluding pulmonary embolism in clinical outcome studies: a systematic review. Ann Intern Med 2003;138:941-951
11. Musset D, et al. Diagnostic strategy for patients with suspected pulmonary embolism: a prospective multicentre outcome study. Lancet 2002;360:1914-1920
12. ten Wolde M, et al. Noninvasive diagnostic work-up of patients with clinically suspected pulmonary embolism: results of a management study. J Thromb Haemostas 2004;2:1110-1117