

# Guidelines on Paediatric Urology

S. Tekgül, H. Riedmiller, D. Beurton, E. Gerharz, P. Hoebeke,  
R. Kocvara, Chr. Radmayr, D. Rohrmann



# TABLE OF CONTENTS

# PAGE

1.	INTRODUCTION	6
1.1	Reference	6
2.	PHIMOSIS	6
2.1	Background	6
2.2	Diagnosis	6
2.3	Treatment	7
2.4	References	7
3.	CRYPTORCHIDISM	8
3.1	Background	8
3.2	Diagnosis	8
3.3	Treatment	9
3.3.1	Medical therapy	9
3.3.2	Surgery	9
	Palpable testis	9
	Non-palpable testis	9
3.4	Prognosis	10
3.5	References	10
4.	HYDROCELE	11
4.1	Background	11
4.2	Diagnosis	11
4.3	Treatment	11
4.4	References	11
5.	HYPOSPADIAS	12
5.1	Background	12
5.2	Diagnosis	12
5.3	Treatment	12
5.4	References	14
6.	CONGENITAL PENILE CURVATURE	15
6.1	Background	15
6.2	Diagnosis	16
6.3	Treatment	16
6.4	References	16
7.	VARICOCELE IN CHILDREN AND ADOLESCENTS	16
7.1	Background	16
7.2	Diagnosis	17
7.3	Therapy	17
7.4	References	18
8.	MICROPENIS	19
8.1	Background	19
8.2	Diagnosis	19
8.3	Treatment	19
8.4	References	20
9.	VOIDING DYSFUNCTION	20
9.1	Background	20
9.2	Definition	20
	9.2.1 Filling-phase dysfunctions	21
	9.2.2 Voiding-phase (emptying) dysfunctions	21
9.3	Diagnosis	21
9.4	Treatment	21
	9.4.1 Standard therapy	21

	9.4.2	Specific interventions	22
	9.5	References	22
10.		ENURESIS (MONOSYMPTOMATIC)	23
	10.1	Background	23
	10.2	Definition	23
	10.3	Diagnosis	23
	10.4	Treatment	23
		10.4.1 Supportive treatment measures	23
		10.4.2 Alarm treatment	24
		10.4.3 Medication	24
	10.5	References	24
11.		MANAGEMENT OF NEUROGENIC BLADDER IN CHILDREN	24
	11.1	Background	24
	11.2	Definition	25
	11.3	Classification	25
	11.4	Urodynamic studies	25
		11.4.1 Method of urodynamic study	26
		11.4.2 Uroflowmetry	26
		11.4.3 Cystometry	26
	11.5	Management	27
		11.5.1 Investigations	27
		11.5.2 Early management with clean intermittent catheterization (CIC)	27
		11.5.3 Medical therapy	27
		11.5.3.1 Botulinum toxin injections	27
		11.5.4 Management of bowel incontinence	27
		11.5.5 Urinary tract infections	28
		11.5.6 Sexuality	28
		11.5.7 Bladder augmentation	28
		11.5.8 Bladder outlet procedures	28
		11.5.9 Continent stoma	28
		11.5.10 Total bladder replacement	29
		11.5.11 Lifelong follow-up of neurogenic bladder patients	29
	11.6	References	29
12.		DILATATION OF THE UPPER URINARY TRACT (URETEROPELVIC JUNCTION [UPJ] AND URETEROVESICAL JUNCTION [UVJ] OBSTRUCTION)	34
	12.1	Background	34
	12.2	Diagnosis	34
		12.2.1 Antenatal ultrasound	34
		12.2.2 Postnatal ultrasound	34
		12.2.3 Voiding cystourethrogram (VCUG)	35
		12.2.4 Diuretic renography	35
	12.3	Treatment	35
		12.3.1 Prenatal management	35
		12.3.2 UPJ obstruction	35
		12.3.3 Megaureter	36
	12.4	Conclusion	36
	12.5	References	36
13.		VESICoureteric Reflux (VUR)	37
	13.1	Background	37
	13.2	Classification	37
	13.3	Diagnostic work-up	38
	13.4	Treatment	38
		13.4.1 Conservative approach	39
		13.4.2 Interventional treatment	39
		13.4.2.1 Open surgery	39
		13.4.2.2 Laparoscopic reflux correction	39

	13.4.2.3 Endoscopic therapy	39
13.5	Follow-up	40
13.6	References	40
14.	URINARY STONE DISEASE IN CHILDREN	42
14.1	Background	42
14.2	Stone formation mechanism, diagnosis of causative factors and medical treatment for specific stone types	42
14.2.1	Calcium stones	42
	Hypercalcuria	42
	Hyperoxaluria	43
	Hypocitraturia	43
14.2.2	Uric acid stones	44
14.2.3	Cystine stones	44
14.2.4	Infection stones (struvite stones)	44
14.3	Clinical presentation and diagnosis of urinary stone disease	44
14.4	Diagnosis	45
14.4.1	Imaging	45
14.4.2	Metabolic evaluation	45
14.5	Management	47
14.5.1	Surgical management of urinary stones	47
14.5.2	Extracorporeal shockwave lithotripsy (ESWL)	47
14.5.3	Percutaneous nephrolithotomy	47
14.5.4	Ureteroscopy	47
14.5.5	Open stone surgery	47
14.6	References	48
15.	OBSTRUCTIVE PATHOLOGY OF RENAL DUPLICATION: URETEROCELE AND ECTOPIC URETER	50
15.1	Background	50
15.1.1	Ureterocele	50
15.1.2	Ectopic ureter	50
15.2	Classification	51
15.2.1	Ectopic ureterocele	51
15.2.2	Orthotopic ureterocele	51
15.2.3	Caecoureterocle	51
15.3	Diagnosis	51
15.3.1	Ureterocele	51
15.3.2	Ectopic ureter	52
15.4	Treatment	52
15.4.1	Ureterocele	52
	15.4.1.1 Early diagnosis	52
	15.4.1.2 Re-evaluation	52
15.4.2	Ectopic ureter	52
15.5	References	52
16.	INTERSEX (ABNORMAL SEXUAL DIFFERENTIATION)	54
16.1	Background	54
16.2	Classification	55
16.2.1	Ovary only (female pseudohermaphrodite)	56
16.2.2	Testis only (male pseudohermaphrodite)	56
16.2.3	Testis plus ovary (true hermaphrodite)	57
16.2.4	Testis plus streak gonad (mixed gonadal dysgenesis)	57
16.2.5	Streak gonad plus streak gonad (pure gonadal dysgenesis)	57
16.3	Diagnosis	57
16.3.1	The neonatal emergency	57
16.3.2	Palpable gonad	58
16.3.3	Laboratory investigations	58
16.3.4	Making a diagnosis	58
16.3.5	Gender assignment	58
16.3.6	Late diagnosis and management	59

16.4	Treatment	59
16.4.1	Genitoplasty	59
	Masculizing genitoplasty	59
	Feminizing genitoplasty	59
16.4.2	Indications for the removal of the gonads	59
	Inappropriate gonadal type for the sex of rearing	59
	High risk of malignancy (gonadoblastoma/dysgerminoma)	59
16.5	References	59
	Chairman's note	60
17.	ABBREVIATIONS USED IN THE TEXT	61

# 1. INTRODUCTION

A collaborative working group consisting of members representing the European Society for Paediatric Urology (ESPU) and the European Association of Urology (EAU) has gathered in an effort to produce the current update of the paediatric urology guidelines. The aim of this close collaboration between a subspecialty group and its parent specialty is to make a document available that may help to increase the quality of care for children with urological problems.

For quite some time paediatric urology informally developed, expanded, matured and established its diverse body of knowledge and expertise and may now be ready to distinguish itself from its parent specialties.

Paediatric urology has recently emerged in many European countries as a distinct subspecialty of both urology and paediatric surgery, and presents a unique challenge in the sense that it covers a large area with many different schools of thought and a huge diversity in management.

Knowledge gained by increasing experience, new technological advances and non-invasive diagnostic screening modalities has had a profound influence on treatment modalities in paediatric urology, a trend that is likely to continue in the years to come. We now have new techniques for the treatment of reflux, our techniques for the treatment of complex congenital anomalies have substantially improved and totally new technologies for bladder replacement and laparoscopic procedures have been developed. There is also an increasing body of knowledge in paediatric urology related to basic research.

Paediatric urology covers a huge field within urology. The scope and complexity of paediatric urology practice continues to expand. Capturing the entire field of paediatric urology in a single guideline document was never an option, but in the years to come this document will be amended and added to on a regular basis.

The guidelines were compiled by the collaborative working group and based on current literature following a systematic review using MEDLINE. Application of a structured analysis of the literature was not possible in many conditions due to a lack of well-designed studies. Whenever possible, statements have been classified in terms of level of evidence and grade of recommendation (1). Due to the limited availability of large randomized controlled trials - influenced also by the fact that a considerable number of treatment options relate to surgical interventions on a large spectrum of different congenital problems - this document will therefore largely be a consensus document.

We hope that you will consider this document a valuable educational resource for your practice and that it will give you guidance in the care of your cases in paediatric urology.

## 1.1. REFERENCE

1. US Department of Health and Human Services. Public Health Service, Agency for Health Care Policy and Research, 1992, pp. 115-127.  
<http://www.ahcpr.gov/>

# 2. PHIMOSIS

## 2.1 Background

At the end of the first year of life, retraction of the foreskin behind the glandular sulcus is possible in only about 50% of boys; this rises to approximately 89% by the age of 3 years. The incidence of phimosis is 8% in 6- to 7-year-olds and just 1% in males aged 16-18 years (1). The phimosis is either primary (physiological) with no sign of scarring, or secondary (pathological) to a scarring such as balanitis xerotica obliterans. Phimosis has to be distinguished from normal agglutination of the foreskin to the glans, which is a physiological phenomenon (2).

The paraphimosis must be regarded as an emergency situation: retraction of a too narrow prepuce behind the glans penis into the glanular sulcus may constrict the shaft and lead to oedema. It interferes with perfusion distally from the constrictive ring and brings a risk of consecutive necrosis.

## 2.2 Diagnosis

The diagnosis of phimosis and paraphimosis is made by physical examination.

If the prepuce is not retractable or only partly retractable and shows a constrictive ring on drawing back over the glans penis, a disproportion between the width of the foreskin and the diameter of the glans penis has to be assumed. In addition to the constricted foreskin, there may be adhesions between the inner surface of the prepuce and the glanular epithelium and/or a fraenum breve. A fraenum breve leads to a ventral deviation of the glans once the foreskin is retracted. If the tip remains narrow and glanular adhesions were separated, then the space is filled with urine during voiding causing the foreskin to balloon outward.

The paraphimosis is characterized by retracted foreskin with the constrictive ring localized at the level

of the sulcus, which prevents replacement of the foreskin over the glans.

### 2.3 Treatment

Treatment of phimosis in children is dependent on the parents' preferences and can be plastic or radical circumcision after completion of the second year of life. Plastic circumcision has the objective of achieving a wide foreskin circumference with full retractability, while the foreskin is preserved (dorsal incision, partial circumcision). However, this procedure carries the potential for recurrence of the phimosis. In the same session, adhesions are released and an associated fraenum breve is corrected by fraenulotomy. Meatoplasty is added if necessary.

An absolute indication for circumcision is secondary phimosis. The indications in primary phimosis are recurrent balanoposthitis and recurrent urinary tract infections in patients with urinary tract abnormalities (3-6) (level of evidence: 2, grade B recommendation). Simple ballooning of the foreskin during micturition is not a strict indication for circumcision.

Routine neonatal circumcision to prevent penile carcinoma is not indicated. Contraindications for circumcision are coagulopathy, an acute local infection and congenital anomalies of the penis, particularly hypospadias or buried penis, because the foreskin may be required for a reconstructive procedure (7,8). Childhood circumcision has an appreciable morbidity and should not be recommended without a medical reason (9-12) (level of evidence: 2, grade B recommendation). As a conservative treatment option of the primary phimosis, a corticoid ointment or cream (0.05-0.1%) can be administered twice a day over a period of 20-30 days (13-16) (level of evidence: 1, grade A recommendation). This treatment has no side effects and the mean bloodspot cortisol levels are not significantly different from an untreated group of patients (17) (level of evidence: 1). Agglutination of the foreskin does not respond to steroid treatment (14) (level of evidence: 2).

Treatment of paraphimosis consists of manual compression of the oedematous tissue with a subsequent attempt to retract the tightened foreskin over the glans penis. Injection of hyaluronidase beneath the narrow band may be helpful to release it (18) (level of evidence: 4, grade C recommendation). If this manoeuvre fails, a dorsal incision of the constrictive ring is required. Depending on the local findings, a circumcision is carried out immediately or can be performed in a second session.

### 2.4 REFERENCES

1. Gairdner D. The fate of the foreskin: a study of circumcision. *Br Med J* 1949;4642:1433-1437.  
[http://www.ncbi.nlm.nih.gov/entrez/query.fcgi?cmd=Retrieve&db=pubmed&dopt=Abstract&list\\_uids=15408299&query\\_hl=9&itool=pubmed\\_docsum](http://www.ncbi.nlm.nih.gov/entrez/query.fcgi?cmd=Retrieve&db=pubmed&dopt=Abstract&list_uids=15408299&query_hl=9&itool=pubmed_docsum)
2. Oster J. Further fate of the foreskin. Incidence of preputial adhesions, phimosis, and smegma among Danish schoolboys. *Arch Dis Child* 1968;43:200-203.  
[http://www.ncbi.nlm.nih.gov/entrez/query.fcgi?cmd=Retrieve&db=pubmed&dopt=Abstract&list\\_uids=5689532&query\\_hl=11&itool=pubmed\\_docsum](http://www.ncbi.nlm.nih.gov/entrez/query.fcgi?cmd=Retrieve&db=pubmed&dopt=Abstract&list_uids=5689532&query_hl=11&itool=pubmed_docsum)
3. Wiswell TE. The prepuce, urinary tract infections, and the consequences. *Pediatrics* 2000;105:860-862.  
[http://www.ncbi.nlm.nih.gov/entrez/query.fcgi?cmd=Retrieve&db=pubmed&dopt=Abstract&list\\_uids=10742334&query\\_hl=14&itool=pubmed\\_docsum](http://www.ncbi.nlm.nih.gov/entrez/query.fcgi?cmd=Retrieve&db=pubmed&dopt=Abstract&list_uids=10742334&query_hl=14&itool=pubmed_docsum)
4. Hiraoka M, Tsukahara H, Ohshima Y, Mayumi M. Meatus tightly covered by the prepuce is associated with urinary tract infection. *Pediatr Int* 2002;44:658-662.  
[http://www.ncbi.nlm.nih.gov/entrez/query.fcgi?cmd=Retrieve&db=pubmed&dopt=Abstract&list\\_uids=12421265&query\\_hl=16&itool=pubmed\\_docsum](http://www.ncbi.nlm.nih.gov/entrez/query.fcgi?cmd=Retrieve&db=pubmed&dopt=Abstract&list_uids=12421265&query_hl=16&itool=pubmed_docsum)
5. To T, Agha M, Dick PT, Feldman W. Cohort study on circumcision of newborn boys and subsequent risk of urinary tract infection. *Lancet* 1998;352:1813-1816.  
[http://www.ncbi.nlm.nih.gov/entrez/query.fcgi?cmd=Retrieve&db=pubmed&dopt=Abstract&list\\_uids=9851381&query\\_hl=19&itool=pubmed\\_docsum](http://www.ncbi.nlm.nih.gov/entrez/query.fcgi?cmd=Retrieve&db=pubmed&dopt=Abstract&list_uids=9851381&query_hl=19&itool=pubmed_docsum)
6. Herndon CDA, McKenna PH, Kolon TF, Gonzales ET, Baker LA, Docimo SG. A multicenter outcomes analysis of patients with neonatal reflux presenting with prenatal hydronephrosis. *J Urol* 1999;162:1203-1208.  
[http://www.ncbi.nlm.nih.gov/entrez/query.fcgi?cmd=Retrieve&db=pubmed&dopt=Abstract&list\\_uids=10458467&query\\_hl=21&itool=pubmed\\_docsum](http://www.ncbi.nlm.nih.gov/entrez/query.fcgi?cmd=Retrieve&db=pubmed&dopt=Abstract&list_uids=10458467&query_hl=21&itool=pubmed_docsum)
7. Thompson HC, King LR, Knox E, Korones SB. Report of the ad hoc task force on circumcision. *Pediatrics* 1975;56:610-611.  
[http://www.ncbi.nlm.nih.gov/entrez/query.fcgi?cmd=Retrieve&db=pubmed&dopt=Abstract&list\\_uids=1174384&query\\_hl=23&itool=pubmed\\_docsum](http://www.ncbi.nlm.nih.gov/entrez/query.fcgi?cmd=Retrieve&db=pubmed&dopt=Abstract&list_uids=1174384&query_hl=23&itool=pubmed_docsum)
8. American Academy of Pediatrics. Report of the Task Force on Circumcision. *Pediatrics* 1989;84:388-391. Erratum in: *Pediatrics* 1989;84:761.  
[http://www.ncbi.nlm.nih.gov/entrez/query.fcgi?cmd=Retrieve&db=pubmed&dopt=Abstract&list\\_uids=2664697&query\\_hl=25&itool=pubmed\\_docsum](http://www.ncbi.nlm.nih.gov/entrez/query.fcgi?cmd=Retrieve&db=pubmed&dopt=Abstract&list_uids=2664697&query_hl=25&itool=pubmed_docsum)

8. Griffiths DM, Atwell JD, Freeman NV. A prospective study of the indications and morbidity of circumcision in children. *Eur Urol* 1985;11:184-187.  
[http://www.ncbi.nlm.nih.gov/entrez/query.fcgi?cmd=Retrieve&db=pubmed&dopt=Abstract&list\\_uids=4029234&query\\_hl=28&itool=pubmed\\_docsum](http://www.ncbi.nlm.nih.gov/entrez/query.fcgi?cmd=Retrieve&db=pubmed&dopt=Abstract&list_uids=4029234&query_hl=28&itool=pubmed_docsum)
9. Christakis DA, Harvey E, Zerr DM, Feudtner C, Wright JA, Connell FA. A trade-off analysis of routine newborn circumcision. *Pediatrics* 2000;105:246-249.  
[http://www.ncbi.nlm.nih.gov/entrez/query.fcgi?cmd=Retrieve&db=pubmed&dopt=Abstract&list\\_uids=10617731&query\\_hl=30&itool=pubmed\\_docsum](http://www.ncbi.nlm.nih.gov/entrez/query.fcgi?cmd=Retrieve&db=pubmed&dopt=Abstract&list_uids=10617731&query_hl=30&itool=pubmed_docsum)
10. Ross JH. Circumcision: Pro and con. In: Elder JS, ed. *Pediatric urology for the general urologist*. New York: Igaku-Shoin, 1996, pp. 49-56.
11. Hutcheson JC. Male neonatal circumcision: indications, controversies and complications. *Urol Clin N Amer* 2004;314:461-467.  
[http://www.ncbi.nlm.nih.gov/entrez/query.fcgi?cmd=Retrieve&db=pubmed&dopt=Abstract&list\\_uids=15313055&query\\_hl=4&itool=pubmed\\_docsum](http://www.ncbi.nlm.nih.gov/entrez/query.fcgi?cmd=Retrieve&db=pubmed&dopt=Abstract&list_uids=15313055&query_hl=4&itool=pubmed_docsum)
12. Monsour MA, Rabinovitch HH, Dean GE. Medical management of phimosis in children: our experience with topical steroids. *J Urol* 1999;162:1162-1164.  
[http://www.ncbi.nlm.nih.gov/entrez/query.fcgi?cmd=Retrieve&db=pubmed&dopt=Abstract&list\\_uids=10458456&query\\_hl=35&itool=pubmed\\_docsum](http://www.ncbi.nlm.nih.gov/entrez/query.fcgi?cmd=Retrieve&db=pubmed&dopt=Abstract&list_uids=10458456&query_hl=35&itool=pubmed_docsum)
13. Chu CC, Chen KC, Diau GY. Topical steroid treatment of phimosis in boys. *J Urol* 1999;162:861-863.  
[http://www.ncbi.nlm.nih.gov/entrez/query.fcgi?cmd=Retrieve&db=pubmed&dopt=Abstract&list\\_uids=10458396&query\\_hl=38&itool=pubmed\\_docsum](http://www.ncbi.nlm.nih.gov/entrez/query.fcgi?cmd=Retrieve&db=pubmed&dopt=Abstract&list_uids=10458396&query_hl=38&itool=pubmed_docsum)
14. ter Meulen PH, Delaere KP. A conservative treatment of phimosis on boys. *Eur Urol* 2001;40:196-199; discussion 200.  
[http://www.ncbi.nlm.nih.gov/entrez/query.fcgi?cmd=Retrieve&db=pubmed&dopt=Abstract&list\\_uids=10458396&query\\_hl=38&itool=pubmed\\_docsum](http://www.ncbi.nlm.nih.gov/entrez/query.fcgi?cmd=Retrieve&db=pubmed&dopt=Abstract&list_uids=10458396&query_hl=38&itool=pubmed_docsum)
15. Elmore JM, Baker LA, Snodgrass WT. Topical steroid therapy as an alternative to circumcision for phimosis in boys younger than 3 years. *J Urol* 2002;168:1746-1747; discussion 1747.  
[http://www.ncbi.nlm.nih.gov/entrez/query.fcgi?cmd=Retrieve&db=pubmed&dopt=Abstract&list\\_uids=12352350&query\\_hl=43&itool=pubmed\\_docsum](http://www.ncbi.nlm.nih.gov/entrez/query.fcgi?cmd=Retrieve&db=pubmed&dopt=Abstract&list_uids=12352350&query_hl=43&itool=pubmed_docsum)
16. Golubovic Z, Milanovic D, Vukadinovic V, Rakic I, Perovic S. The conservative treatment of phimosis in boys. *Br J Urol* 1996;78:786-788.  
[http://www.ncbi.nlm.nih.gov/entrez/query.fcgi?cmd=Retrieve&db=pubmed&dopt=Abstract&list\\_uids=8976781&query\\_hl=32&itool=pubmed\\_docsum](http://www.ncbi.nlm.nih.gov/entrez/query.fcgi?cmd=Retrieve&db=pubmed&dopt=Abstract&list_uids=8976781&query_hl=32&itool=pubmed_docsum)
17. DeVries CR, Miller AK, Packer MG. Reduction of paraphimosis with hyaluronidase (see comments). *Urology* 1996;48:464-465.  
[http://www.ncbi.nlm.nih.gov/entrez/query.fcgi?cmd=Retrieve&db=pubmed&dopt=Abstract&list\\_uids=8804504&query\\_hl=50&itool=pubmed\\_docsum](http://www.ncbi.nlm.nih.gov/entrez/query.fcgi?cmd=Retrieve&db=pubmed&dopt=Abstract&list_uids=8804504&query_hl=50&itool=pubmed_docsum)

## 3. CRYPTORCHIDISM

### 3.1 Background

At the age of 1 year, almost 1% of all full-term male infants are affected by this most common congenital anomaly associated with the genitalia of newborn males (1). Since the knowledge of the location and existence of the testis directly influences clinical management, categorization into palpable and non-palpable testis seems to be most appropriate.

Retractile testes do not need any form of treatment except observation as they can become ascendant. Retractile testes have completed their descent but may be found in the groin because of a strong cremasteric reflex (2).

In the case of bilateral non-palpable testes and any suggestion of sexual differentiation problems, such as hypospadias, urgent endocrinological and genetic evaluation is mandatory (3) (level of evidence: 3, grade B recommendation).

### 3.2 Diagnosis

A physical examination is the only method of differentiating between palpable or non-palpable testes. There is no additional benefit in performing ultrasound, computed tomography (CT), magnetic resonance imaging (MRI) or angiography.

Clinical examination includes a visual description of the scrotum and an examination of the child while



supine and in crossed-leg position. The examiner should inhibit the cremasteric reflex with his non-dominant hand right above the symphysis in the groin region before touching, or reaching for, the scrotum. The groin region may be 'milked' towards the scrotum in an attempt to move the testis into the scrotum. This manoeuvre also allows the differentiation to be made between an inguinal testis and enlarged lymph nodes that could give the impression of an undescended testis.

A retractile testis can generally be brought into the scrotum, where it will remain until a cremasteric reflex (touching the inner thigh skin) will retract it again into the groin (4).

A unilateral non-palpable testis and an enlarged contralateral testis may suggest testicular absence or atrophy, but this finding is not specific and does not preclude surgical exploration.

Specific visual attention should be given to the femoral, penile and perineal region in the case of an inguinal non-palpable testis to exclude an ectopic testis.

There is no reliable examination to confirm or rule out an intra-abdominal, inguinal and absent/vanishing testis (non-palpable testis), except for diagnostic laparoscopy (5) (level of evidence: 1, grade A recommendation). Before instigating laparoscopic assessment an examination under general anaesthesia is recommended because some originally non-palpable testes are palpable under anaesthetic conditions.

### 3.3 Treatment

If a testis has not descended by the age of 1 year, there is no benefit in waiting for a spontaneous descent. To prevent histological deterioration, treatment should be carried out and finished before 12-18 months of age (6).

#### 3.3.1 Medical therapy

Medical therapy using human chorionic gonadotrophin (hCG) or gonadotrophin-releasing hormone (GnRH) is based on the hormonal dependence of testicular descent with success rates of a maximum of 20% (7,8). Hormonal therapy for testicular descent has lower success rates the higher the undescended testis is located. HCG is used in a dosage of 6.000 to 9.000 units depending on weight and age and GnRH in a dosage of 1.2 mg/day divided into three dosages per day for 4 weeks using a nasal spray.

However, medical treatment can be beneficial before (dosage as described earlier) or after (low intermittent dosages) surgical orchidolysis and orchidopexy (9) (level of evidence: 1, grade A recommendation).

#### 3.3.2 Surgery

##### *Palpable testis*

Surgery for the palpable testis includes orchidofuniculolysis and orchidopexy, via an inguinal approach, with success rates of up to 92% (10). It is important to remove and dissect all cremasteric fibres to prevent secondary retraction. Associated problems, such as an open processus vaginalis, must be carefully dissected and closed. It is recommended that the testis is placed in a subdartos pouch. With regard to sutures, there should either be no fixation sutures or they should be made between the tunica vaginalis and the dartos musculature.

The lymph drainage of a testis that has undergone surgery for orchidopexy has been changed from iliac drainage to iliac and inguinal drainage (important in the event of later malignancy).

##### *Non-palpable testis*

In the situation of a non-palpable testis, inguinal surgical exploration with the possibility of performing laparoscopy should be attempted. There is a significant chance of finding the testis via an inguinal incision, but in rare cases, it is necessary to search into the abdomen if there are no vessels or vas deferens in the groin. Laparoscopy is the most appropriate way of examining the abdomen for a testis. In addition, either removal or orchidolysis and orchidopexy can be performed via laparoscopic access (11). Before starting diagnostic laparoscopy it is recommended to examine the child again under general anaesthesia since a previous non-palpable testes might now be palpable under anaesthetic conditions.

An intra-abdominal testis in a 10-year-old boy or older with a normal contralateral testis should be removed. In bilateral intra-abdominal testes, or in a boy younger than 10 years, a one-stage or two-stage Fowler-Stephens procedure can be performed. In the event of a two-stage procedure, the spermatic vessels are either laparoscopically clipped or coagulated proximal to the testis to allow development of collateral vasculature (12). The second-stage procedure, in which the testis is brought directly over the symphysis and next to the bladder into the scrotum, can also be performed by laparoscopy 6 months later. The testicular survival rate in a one-stage procedure varies between 50% and 60%, with success rates rising up to 90% in a two-stage procedure (9). Microvascular autotransplantation can also be performed with 90% testicular survival rate. However, the procedure requires very skilful and experienced surgical techniques (13).

### 3.4 Prognosis

Boys with one undescended testis have a lower fertility rate but the same paternity rate as boys with bilateral descended testes. Boys with bilateral undescended testes have a lower fertility and paternity rate.

Boys with an undescended testis have a 20-fold higher chance of developing testicular malignancy, a risk which is uninfluenced by any kind of treatment. Screening both during and after puberty is therefore recommended for these boys.

Boys with retractile testes do not need medical or surgical treatment but require close follow-up until puberty.

Due to the lack of spontaneous testicular descent after the age of 1 year, and because of the potential loss of testicular quality, it is recommended that surgical orchidolysis and orchidopexy are performed at the latest by 12-18 months of age. To date, it seems that pre- or post-operative hormonal treatment may have a beneficial effect on fertility later in life.

### 3.5 REFERENCES

1. Berkowitz GS, Lapinski RH, Dolgin SE, Gazella JG, Bodian CA, Holzman IR. Prevalence and natural history of cryptorchidism. *Pediatrics* 1993;92:44-49.  
[http://www.ncbi.nlm.nih.gov/entrez/query.fcgi?cmd=Retrieve&db=pubmed&dopt=Abstract&list\\_uids=8100060&query\\_hl=12&itool=pubmed\\_docsum](http://www.ncbi.nlm.nih.gov/entrez/query.fcgi?cmd=Retrieve&db=pubmed&dopt=Abstract&list_uids=8100060&query_hl=12&itool=pubmed_docsum)
2. Caesar RE, Kaplan GW. The incidence of the cremasteric reflex in normal boys. *J Urol* 1994;152:779-780.  
[http://www.ncbi.nlm.nih.gov/entrez/query.fcgi?cmd=Retrieve&db=pubmed&dopt=Abstract&list\\_uids=7912745&query\\_hl=16&itool=pubmed\\_docsum](http://www.ncbi.nlm.nih.gov/entrez/query.fcgi?cmd=Retrieve&db=pubmed&dopt=Abstract&list_uids=7912745&query_hl=16&itool=pubmed_docsum)
3. Rajfer J, Walsh PC. The incidence of intersexuality in patients with hypospadias and cryptorchidism. *J Urol* 1976;116:769-770.  
[http://www.ncbi.nlm.nih.gov/entrez/query.fcgi?cmd=Retrieve&db=pubmed&dopt=Abstract&list\\_uids=12377&query\\_hl=14&itool=pubmed\\_docsum](http://www.ncbi.nlm.nih.gov/entrez/query.fcgi?cmd=Retrieve&db=pubmed&dopt=Abstract&list_uids=12377&query_hl=14&itool=pubmed_docsum)
4. Rabinowitz R, Hulbert WC Jr. Late presentation of cryptorchidism: the etiology of testicular re-ascent. *J Urol* 1997;157:1892-1894.  
[http://www.ncbi.nlm.nih.gov/entrez/query.fcgi?cmd=Retrieve&db=pubmed&dopt=Abstract&list\\_uids=9112557&query\\_hl=19&itool=pubmed\\_docsum](http://www.ncbi.nlm.nih.gov/entrez/query.fcgi?cmd=Retrieve&db=pubmed&dopt=Abstract&list_uids=9112557&query_hl=19&itool=pubmed_docsum)
5. Cisek LJ, Peters CA, Atala A, Bauer SB, Diamond DA, Retik AB. Current findings in diagnostic laparoscopic evaluation of the nonpalpable testis. *J Urol* 1998;160:1145-1149.  
[http://www.ncbi.nlm.nih.gov/entrez/query.fcgi?cmd=Retrieve&db=pubmed&dopt=Abstract&list\\_uids=9719296&query\\_hl=21&itool=pubmed\\_docsum](http://www.ncbi.nlm.nih.gov/entrez/query.fcgi?cmd=Retrieve&db=pubmed&dopt=Abstract&list_uids=9719296&query_hl=21&itool=pubmed_docsum)
6. Huff DS, Hadziselimovic F, Snyder HM 3rd, Blythe B, Duckett JW. Histologic maldevelopment of unilaterally cryptorchid testes and their descended partners. *Eur J Pediatr* 1993;152 (Suppl):S11-S14.  
[http://www.ncbi.nlm.nih.gov/entrez/query.fcgi?cmd=Retrieve&db=pubmed&dopt=Abstract&list\\_uids=8101802&query\\_hl=24&itool=pubmed\\_docsum](http://www.ncbi.nlm.nih.gov/entrez/query.fcgi?cmd=Retrieve&db=pubmed&dopt=Abstract&list_uids=8101802&query_hl=24&itool=pubmed_docsum)
7. Rajfer J, Handelsman DJ, Swerdloff RS, Hurwitz R, Kaplan H, Vandergast T, Ehrlich RM. Hormonal therapy of cryptorchidism. A randomized, double-blind study comparing human chorionic gonadotropin and gonadotropin-releasing hormone. *N Engl J Med* 1986;314:466-470.  
[http://www.ncbi.nlm.nih.gov/entrez/query.fcgi?cmd=Retrieve&db=pubmed&dopt=Abstract&list\\_uids=2868413&query\\_hl=26&itool=pubmed\\_docsum](http://www.ncbi.nlm.nih.gov/entrez/query.fcgi?cmd=Retrieve&db=pubmed&dopt=Abstract&list_uids=2868413&query_hl=26&itool=pubmed_docsum)
8. Pyorala S, Huttunen NP, Uhari M. A review and meta-analysis of hormonal treatment of cryptorchidism. *J Clin Endocrinol Metab* 1995;80:2795-2799.  
[http://www.ncbi.nlm.nih.gov/entrez/query.fcgi?cmd=Retrieve&db=pubmed&dopt=Abstract&list\\_uids=7673426&query\\_hl=28&itool=pubmed\\_docsum](http://www.ncbi.nlm.nih.gov/entrez/query.fcgi?cmd=Retrieve&db=pubmed&dopt=Abstract&list_uids=7673426&query_hl=28&itool=pubmed_docsum)
9. Radmayr C, Oswald J, Schwentner C, Neururer R, Peschel R, Bartsch G. Long-term outcome of laparoscopically managed nonpalpable testes. *J Urol* 2003;170:2409-2411.  
[http://www.ncbi.nlm.nih.gov/entrez/query.fcgi?cmd=Retrieve&db=pubmed&dopt=Abstract&list\\_uids=14634439&query\\_hl=37&itool=pubmed\\_docsum](http://www.ncbi.nlm.nih.gov/entrez/query.fcgi?cmd=Retrieve&db=pubmed&dopt=Abstract&list_uids=14634439&query_hl=37&itool=pubmed_docsum)
10. Docimo SG. The results of surgical therapy for cryptorchidism: a literature review and analysis. *J Urol* 1995;154:1148-1152.  
[http://www.ncbi.nlm.nih.gov/entrez/query.fcgi?cmd=Retrieve&db=pubmed&dopt=Abstract&list\\_uids=7637073&query\\_hl=30&itool=pubmed\\_docsum](http://www.ncbi.nlm.nih.gov/entrez/query.fcgi?cmd=Retrieve&db=pubmed&dopt=Abstract&list_uids=7637073&query_hl=30&itool=pubmed_docsum)
11. Jordan GH, Winslow BH. Laparoscopic single stage and staged orchiopexy. *J Urol* 1994;152:1249-1252.  
[http://www.ncbi.nlm.nih.gov/entrez/query.fcgi?cmd=Retrieve&db=pubmed&dopt=Abstract&list\\_uids=7915336&query\\_hl=32&itool=pubmed\\_docsum](http://www.ncbi.nlm.nih.gov/entrez/query.fcgi?cmd=Retrieve&db=pubmed&dopt=Abstract&list_uids=7915336&query_hl=32&itool=pubmed_docsum)

12. Bloom DA. Two-step orchiopexy with pelviscopic clip ligation of the spermatic vessels. *J Urol* 1991;145:1030-1033.  
[http://www.ncbi.nlm.nih.gov/entrez/query.fcgi?cmd=Retrieve&db=pubmed&dopt=Abstract&list\\_uids=1673160&query\\_hl=35&itool=pubmed\\_docsum](http://www.ncbi.nlm.nih.gov/entrez/query.fcgi?cmd=Retrieve&db=pubmed&dopt=Abstract&list_uids=1673160&query_hl=35&itool=pubmed_docsum)
13. Wacksman J, Billmire DA, Lewis AG, Sheldon CA. Laparoscopically assisted testicular autotransplantation for management of the intraabdominal undescended testis. *J Urol* 1996;156:772-774.  
[http://www.ncbi.nlm.nih.gov/entrez/query.fcgi?cmd=Retrieve&db=pubmed&dopt=Abstract&list\\_uids=8683780&query\\_hl=41&itool=pubmed\\_docsum](http://www.ncbi.nlm.nih.gov/entrez/query.fcgi?cmd=Retrieve&db=pubmed&dopt=Abstract&list_uids=8683780&query_hl=41&itool=pubmed_docsum)

## 4. HYDROCELE

### 4.1 Background

Hydrocele is defined as a collection of fluid between the parietal and visceral layer of tunica vaginalis (1). Pathogenesis of hydrocele is based on an imbalance between the secretion and reabsorption of this fluid. This is in contrast with inguinal hernia, which is defined as the protrusion of a portion of organs or tissues through the abdominal wall (2). Incomplete obliteration of the processus vaginalis peritonei results in formation of various types of communicating hydrocele alone or connected with other intrascrotal pathology (hernia). The exact time of obliteration of processus vaginalis is not known. It persists in approximately 80-94% of newborns and in 20% of adults (3). If complete obliteration of processus vaginalis occurs with patency of midportion, an hydrocele of the cord occurs. Scrotal hydroceles without associated patency of the processus vaginalis are encountered in newborns as well (4). Non-communicating hydroceles are found secondary to minor trauma, testicular torsion, epididymitis, varicocele operation or may appear as a recurrence after primary repair of a communicating hydrocele.

### 4.2 Diagnosis

The classic description of a communicating hydrocele is that of an hydrocele that vacillates in size, usually related to activity. It may be diagnosed by history; physical investigation and transillumination of the scrotum make the diagnosis in the majority of cases (5). If the diagnosis is that of an hydrocele, there will be no history of reducibility and no associated symptoms; the swelling is translucent, smooth and usually non-tender. If there are any doubts about the character of an intrascrotal mass, scrotal ultrasound should be performed and has nearly 100% sensitivity in detecting intrascrotal lesions. Doppler ultrasound studies help to distinguish hydroceles from varicocele and testicular torsion, although these conditions may also be accompanied by an hydrocele.

### 4.3 Treatment

In the majority of infants, the surgical treatment of hydrocele is not indicated within the first 12-24 months because of the tendency for spontaneous resolution (level of evidence: 4, grade C recommendation). Early surgery is indicated if there is suspicion of a concomitant inguinal hernia or underlying testicular pathology (6). The question of contralateral disease should be addressed by both history and examination at the time of initial consultation (5). Persistence of a simple scrotal hydrocele beyond 24 months of age may be an indication for surgical correction. However, there is no evidence that this type of hydrocele risks testicular damage. In the paediatric age group, the operation consists of ligation of patent processus vaginalis via inguinal incision and the distal stump is left open, whereas in hydrocele of the cord the cystic mass is excised or unroofed (1,5,6) (level of evidence: 4, grade C recommendation). In expert hands, the incidence of testicular damage during hydrocele or inguinal hernia repair is very low (0.3%) (level of evidence: 3, grade B recommendation). Sclerosing agents should not be used because of the risk of chemical peritonitis in communicating processus vaginalis peritonei (5,6) (level of evidence: 4, grade C recommendation). The scrotal approach (Lord or Jaboulay technique) is used in the treatment of a secondary non-communicating hydrocele.

### 4.4 REFERENCES

1. Kapur P, Caty MG, Glick PL. Pediatric hernias and hydroceles. *Pediatric Clin North Am* 1998;45:773-789.  
[http://www.ncbi.nlm.nih.gov/entrez/query.fcgi?cmd=Retrieve&db=pubmed&dopt=Abstract&list\\_uids=9728185&query\\_hl=1&itool=pubmed\\_docsum](http://www.ncbi.nlm.nih.gov/entrez/query.fcgi?cmd=Retrieve&db=pubmed&dopt=Abstract&list_uids=9728185&query_hl=1&itool=pubmed_docsum)
2. Barthold JS, Kass EJ. Abnormalities of the penis and scrotum. In: Belman AB, King LR, Kramer SA, eds. *Clinical pediatric urology*. 4th edn. London: Martin Dunitz, 2002, pp. 1093-1124.

3. Schneck FX, Bellinger MF. Abnormalities of the testes and scrotum and their surgical management. In: Walsh PC, Retik AB, Vaughan ED, Wein AJ, eds. *Campbell's urology*. 8th edn. Philadelphia: WB Saunders, 2002, pp. 2353-2394.
4. Rubenstein RA, Dogra VS, Seftel AD, Resnick MI. Benign intrascrotal lesions. *J Urol* 2004; 171:1765-1772.  
[http://www.ncbi.nlm.nih.gov/entrez/query.fcgi?cmd=Retrieve&db=pubmed&dopt=Abstract&list\\_uids=15076274&query\\_hl=7&itool=pubmed\\_docsum](http://www.ncbi.nlm.nih.gov/entrez/query.fcgi?cmd=Retrieve&db=pubmed&dopt=Abstract&list_uids=15076274&query_hl=7&itool=pubmed_docsum)
5. Skoog SJ. Benign and malignant pediatric scrotal masses. *Pediatr Clin North Am* 1997;44:1229-1250.  
[http://www.ncbi.nlm.nih.gov/entrez/query.fcgi?cmd=Retrieve&db=pubmed&dopt=Abstract&list\\_uids=9326960&query\\_hl=4&itool=pubmed\\_docsum](http://www.ncbi.nlm.nih.gov/entrez/query.fcgi?cmd=Retrieve&db=pubmed&dopt=Abstract&list_uids=9326960&query_hl=4&itool=pubmed_docsum)
6. Stringer MD, Godbole PP. Patent processus vaginalis. In: Gearhart JP, Rink RC, Mouriquand PD, eds. *Pediatric urology*. Philadelphia: WB Saunders, 2001, pp. 755-762.

## 5. HYPOSPADIAS

### 5.1 Background

Hypospadias can be defined as hypoplasia of the tissues forming the ventral aspect of the penis beyond the division of the corpus spongiosum. Hypospadias is usually classified according to the anatomical location of the proximally displaced urethral orifice:

- distal-anterior hypospadias (located on the glans or distal shaft of the penis and the most common type of hypospadias)
- intermediate-middle (penile)
- proximal-posterior (penoscrotal, scrotal, perineal).

The pathology may be much more severe after skin release. Risk factors for hypospadias include endocrine disorders (very few cases), young and old mothers, babies of low birth-weight and being a twin. A significant increase in the incidence of hypospadias in the population over the last 20 years has raised the possibility of a role for environmental factors (hormonal disruptors and pesticides) (1-3).

### 5.2 Diagnosis

Diagnosis should be made at birth (with the exception of the megameatus intact prepuce variant). Apart from a description of the local findings (position, shape and width of the orifice, presence of atretic urethra and division of corpus spongiosum, appearance of the praeputial hood and scrotum, size of the penis, information on the curvature of the penis on erection), the diagnostic evaluation includes assessment of associated anomalies:

- cryptorchidism (up to 10%)
- open processus vaginalis or inguinal hernia (9-15%).

Severe hypospadias with unilaterally or bilaterally impalpable testis, or with ambiguous genitalia, require a complete genetic and endocrine work-up very soon after birth to exclude intersexuality, especially congenital adrenal hyperplasia. Urine trickling and ballooning of the urethra requires exclusion of meatal stenosis. The incidence of upper urinary tract anomalies does not differ from the general population, except in very severe forms of hypospadias (1,2).

### 5.3 Treatment

Differentiation between functionally necessary and aesthetically feasible operative procedures is important for therapeutic decision-making. The functional indications for surgery are proximally located meatus, ventrally deflected urinary stream, meatal stenosis, and curved penis. The cosmetic indications, which are strongly linked to the parental or future patient's psychology, are abnormally located meatus, cleft glans, rotated penis with abnormal cutaneous raphe, praeputial hood, penoscrotal transposition and split scrotum.

Since all surgical procedures carry the risk of complications, thorough pre-operative counselling of the parents is crucial.

The therapeutic objectives are:

- to correct the penile curvature
- to form a neo-urethra of an adequate size
- to bring the neomeatus to the tip of the glans, if possible
- to achieve an overall acceptable cosmetic appearance of the boy's genitalia (1,2).

The use of magnifying spectacles and special fine synthetic absorbable suture materials (6.0-7.0) are required. As in any penile surgery, an exceptional prudence should be adopted with the use of cautery.

Knowledge of a variety of surgical reconstructive techniques, wound care and post-operative treatment are essential for a satisfactory outcome. Pre-operative hormonal treatment with local or parenteral application of testosterone, dihydrotestosterone or beta-chorionic gonadotrophin can be helpful in patients with a small penis or for repeat surgery. The age at surgery for primary hypospadias repair is usually 6-18 (24) months (2) (level of evidence: 4, grade C recommendation).

Penile curvature, if present, is often released by degloving the penis (skin chordee) and by excision of the connective tissue of the genuine chordee on the ventral aspect of the penis. The urethral plate has well-vascularized connective tissue and does not cause curvature in most cases. The residual chordee (curvature) is caused by corporeal disproportion and requires a dorsal orthoplasty (modification of Nesbit dorsal corporeal plication) (4) (level of evidence: 3, grade B recommendation).

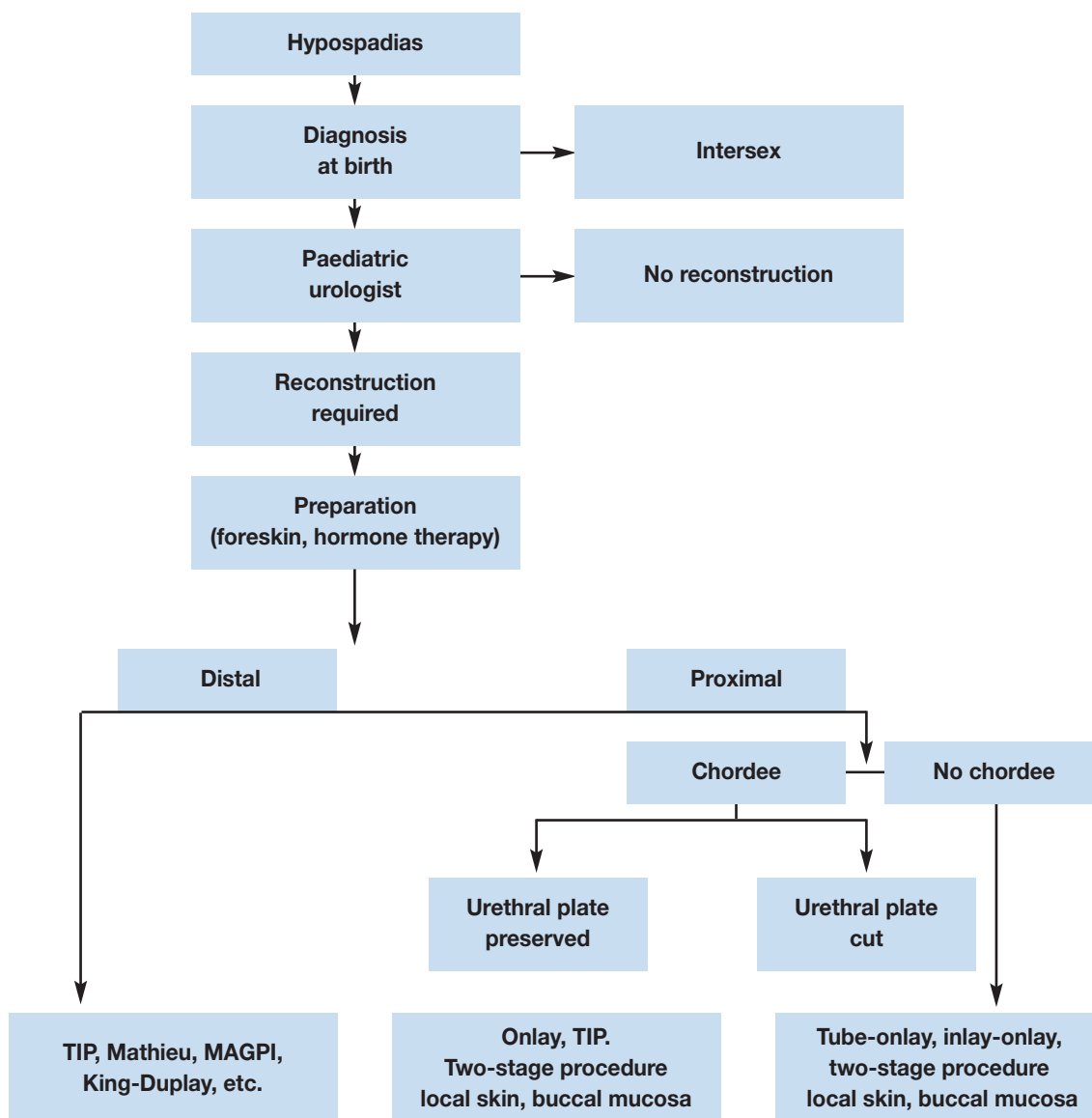
Preservation of the well-vascularized urethral plate and its use for urethral reconstruction has become the mainstay of hypospadias repair (5). If the urethral plate is wide, it can be tubularized following the Thiersch-Duplay technique. If the plate is too narrow to be tubularized, midline-relaxing incision of the plate and reconstruction according to the Snodgrass technique is recommended in distal hypospadias and also in proximal hypospadias but with a higher complication rate (6-9). The onlay technique is preferred in proximal hypospadias and in cases of unhealthy or too narrow plate. For distal forms of hypospadias, a range of other techniques is available (e.g. Mathieu, urethral advancement, etc.) (10) (level of evidence: 2, grade B recommendation).

If the continuity of the urethral plate cannot be preserved, a modification of the tubularized flap, such as a tube-onlay or an inlay-onlay flap, is used to prevent urethral stricture (11,12) (level of evidence: 3, grade C recommendation). In this situation, as well as in severe scrotal or penoscrotal hypospadias, a two-stage procedure may be an option (13,14). If praeputial or penile skin is not available or there are signs of balanitis xerotica obliterans, buccal mucosa graft is used in the onlay or two-stage repairs (15,16) (level of evidence: 3, grade C recommendation). For re-do hypospadias repairs, no definite guidelines can be given. All above-mentioned procedures are used in a different, often modified, way in each particular patient.

After formation of the neo-urethra, the procedure is completed by glansplasty and by reconstruction of the penile skin. If there is a shortage of skin covering, the praeputial double-face technique or placement of the suture line into the scrotum may be used. In countries where circumcision is not routinely performed, praeputial reconstruction can be considered. However, in tubularized incised urethral plate (TIP) repair, the parents should be advised that use of a praeputial dartos flap reduces the fistula rate (level of evidence: 2, grade B recommendation) (6).

Urine is drained with a transurethral dripping stent or with a suprapubic tube. Some use no drainage after distal hypospadias repair. A circular dressing with slight compression and prophylactic antibiotics are established procedures. There is a large variety of duration of stenting and dressings. No recommendation can be given due to the lack of evidence available.

Figure 1: Algorithm for the management of hypospadias



MAGPI = meatal advancement and glanuloplasty (MAGPI); TIP = tubularized incised urethral plate.

#### 5.4 REFERENCES

1. Belman AB. Hypospadias and chordee. In: Belman AB, King LR, Kramer SA, eds. *Clinical pediatric urology*. 4th edn. London: Martin Dunitz, 2002, pp. 1061-1092.
2. Mouriquand PDE, Mure Y. Hypospadias. In: *Pediatric urology*. Gearhart JP, Rink RR, Mouriquand PDE, eds. Philadelphia: WB Saunders 2001, pp. 713-728.
3. Weidner IS, Moller H, Jensen TK, Skakkebaek NE. Risk factors for cryptorchidism and hypospadias. *J Urol* 1999;161:1606-1609.  
[http://www.ncbi.nlm.nih.gov/entrez/query.fcgi?cmd=Retrieve&db=pubmed&dopt=Abstract&list\\_uids=10210427&query\\_hl=156&itool=pubmed\\_docsum](http://www.ncbi.nlm.nih.gov/entrez/query.fcgi?cmd=Retrieve&db=pubmed&dopt=Abstract&list_uids=10210427&query_hl=156&itool=pubmed_docsum)
4. Baskin LS, Duckett JW, Ueoka K, Seibold J, Snyder HM 3rd. Changing concepts of hypospadias curvature lead to more onlay island flap procedures. *J Urol* 1994;151:191-196.  
[http://www.ncbi.nlm.nih.gov/entrez/query.fcgi?cmd=Retrieve&db=pubmed&dopt=Abstract&list\\_uids=8254812&query\\_hl=132&itool=pubmed\\_docsum](http://www.ncbi.nlm.nih.gov/entrez/query.fcgi?cmd=Retrieve&db=pubmed&dopt=Abstract&list_uids=8254812&query_hl=132&itool=pubmed_docsum)
5. Hollowell JG, Keating MA, Snyder HM 3rd, Duckett JW. Preservation of the urethral plate in hypospadias repair: extended applications and further experience with the onlay island flap urethroplasty. *J Urol* 1990;143:98-101; discussion 100-101.  
[http://www.ncbi.nlm.nih.gov/entrez/query.fcgi?cmd=Retrieve&db=pubmed&dopt=Abstract&list\\_uids=2294275&query\\_hl=140&itool=pubmed\\_docsum](http://www.ncbi.nlm.nih.gov/entrez/query.fcgi?cmd=Retrieve&db=pubmed&dopt=Abstract&list_uids=2294275&query_hl=140&itool=pubmed_docsum)

6. El-Sherbiny MT, Hafez AT, Dawaba MS, Shorrab AA, Bazeed MA. Comprehensive analysis of tubularized incised-plate urethroplasty in primary and re-operative hypospadias. *BJU Int* 2004;93:1057-1061.  
[http://www.ncbi.nlm.nih.gov/entrez/query.fcgi?cmd=Retrieve&db=pubmed&dopt=Abstract&list\\_uids=15142164&query\\_hl=26&itool=pubmed\\_docsum](http://www.ncbi.nlm.nih.gov/entrez/query.fcgi?cmd=Retrieve&db=pubmed&dopt=Abstract&list_uids=15142164&query_hl=26&itool=pubmed_docsum)
7. Riccabona M, Oswald J, Koen M, Beckers G, Schrey A, Lusuardi L. Comprehensive analysis of six years experience in tubularized incised plate urethroplasty and its extended application in primary and secondary hypospadias repair. *Eur Urol* 2003;44:714-719.  
[http://www.ncbi.nlm.nih.gov/entrez/query.fcgi?cmd=Retrieve&db=pubmed&dopt=Abstract&list\\_uids=14644125&query\\_hl=150&itool=pubmed\\_docsum](http://www.ncbi.nlm.nih.gov/entrez/query.fcgi?cmd=Retrieve&db=pubmed&dopt=Abstract&list_uids=14644125&query_hl=150&itool=pubmed_docsum)
8. Snodgrass W, Koyle M, Manzoni G, Hurwitz R, Caldamone A, Ehrlich R. Tubularized incised plate hypospadias repair: results of a multicenter experience. *J Urol* 1996;156:839-841.  
[http://www.ncbi.nlm.nih.gov/entrez/query.fcgi?cmd=Retrieve&db=pubmed&dopt=Abstract&list\\_uids=8683797&query\\_hl=152&itool=pubmed\\_docsum](http://www.ncbi.nlm.nih.gov/entrez/query.fcgi?cmd=Retrieve&db=pubmed&dopt=Abstract&list_uids=8683797&query_hl=152&itool=pubmed_docsum)
9. Snodgrass WT, Lorenzo A. Tubularized incised-plate urethroplasty for proximal hypospadias. *BJU Int* 2002;89:90-93.  
[http://www.ncbi.nlm.nih.gov/entrez/query.fcgi?cmd=Retrieve&db=pubmed&dopt=Abstract&list\\_uids=11849169&query\\_hl=154&itool=pubmed\\_docsum](http://www.ncbi.nlm.nih.gov/entrez/query.fcgi?cmd=Retrieve&db=pubmed&dopt=Abstract&list_uids=11849169&query_hl=154&itool=pubmed_docsum)
10. Meyer-Junghanel L, Petersen C, Mildenerger H. Experience with repair of 120 hypospadias using Mathieu's procedure. *Eur J Pediatr Surg* 1995;5:355-357.  
[http://www.ncbi.nlm.nih.gov/entrez/query.fcgi?cmd=Retrieve&db=pubmed&dopt=Abstract&list\\_uids=8773227&query\\_hl=145&itool=pubmed\\_docsum](http://www.ncbi.nlm.nih.gov/entrez/query.fcgi?cmd=Retrieve&db=pubmed&dopt=Abstract&list_uids=8773227&query_hl=145&itool=pubmed_docsum)
11. Kocvara R, Dvoracek J. Inlay-onlay flap urethroplasty for hypospadias and urethral stricture repair. *J Urol* 1997;158:2142-2145.  
[http://www.ncbi.nlm.nih.gov/entrez/query.fcgi?cmd=Retrieve&db=pubmed&dopt=Abstract&list\\_uids=9366331&query\\_hl=142&itool=pubmed\\_docsum](http://www.ncbi.nlm.nih.gov/entrez/query.fcgi?cmd=Retrieve&db=pubmed&dopt=Abstract&list_uids=9366331&query_hl=142&itool=pubmed_docsum)
12. Perovic S, Vukadinovic V. Onlay island flap urethroplasty for severe hypospadias: a variant of the technique. *J Urol* 1994;151:711-714.  
[http://www.ncbi.nlm.nih.gov/entrez/query.fcgi?cmd=Retrieve&db=pubmed&dopt=Abstract&list\\_uids=8308994&query\\_hl=20&itool=pubmed\\_docsum](http://www.ncbi.nlm.nih.gov/entrez/query.fcgi?cmd=Retrieve&db=pubmed&dopt=Abstract&list_uids=8308994&query_hl=20&itool=pubmed_docsum)
13. Bracka A. Hypospadias repair: the two-stage alternative. *Br J Urol* 1995;76(Suppl 3):31-41.  
[http://www.ncbi.nlm.nih.gov/entrez/query.fcgi?cmd=Retrieve&db=pubmed&dopt=Abstract&list\\_uids=8535768&query\\_hl=134&itool=pubmed\\_docsum](http://www.ncbi.nlm.nih.gov/entrez/query.fcgi?cmd=Retrieve&db=pubmed&dopt=Abstract&list_uids=8535768&query_hl=134&itool=pubmed_docsum)
14. Retik AB, Bauer SB, Mandell J, Peters CA, Colodny A, Atala A. Management of severe hypospadias with a 2-stage repair. *J Urol* 1994;152:749-751.  
[http://www.ncbi.nlm.nih.gov/entrez/query.fcgi?cmd=Retrieve&db=pubmed&dopt=Abstract&list\\_uids=8022010&query\\_hl=148&itool=pubmed\\_docsum](http://www.ncbi.nlm.nih.gov/entrez/query.fcgi?cmd=Retrieve&db=pubmed&dopt=Abstract&list_uids=8022010&query_hl=148&itool=pubmed_docsum)
15. Ahmed S, Gough DC. Buccal mucosal graft for secondary hypospadias repair and urethral replacement. *Br J Urol* 1997;80:328-330.  
[http://www.ncbi.nlm.nih.gov/entrez/query.fcgi?cmd=Retrieve&db=pubmed&dopt=Abstract&list\\_uids=9284210&query\\_hl=129&itool=pubmed\\_docsum](http://www.ncbi.nlm.nih.gov/entrez/query.fcgi?cmd=Retrieve&db=pubmed&dopt=Abstract&list_uids=9284210&query_hl=129&itool=pubmed_docsum)
16. Caldamone AA, Edstrom LE, Koyle MA, Rabinowitz R, Hulbert WC. Buccal mucosal grafts for urethral reconstruction. *Urology* 1998;51(5A Suppl):15-19.  
[http://www.ncbi.nlm.nih.gov/entrez/query.fcgi?cmd=Retrieve&db=pubmed&dopt=Abstract&list\\_uids=9610551&query\\_hl=136&itool=pubmed\\_docsum](http://www.ncbi.nlm.nih.gov/entrez/query.fcgi?cmd=Retrieve&db=pubmed&dopt=Abstract&list_uids=9610551&query_hl=136&itool=pubmed_docsum)

## 6. CONGENITAL PENILE CURVATURE

### 6.1 Background

Penile curvature may be ventral, dorsal or lateral. Most of ventral curvatures are associated with hypospadias due to chordee or ventral dysplasia of cavernous bodies (1). Similarly, the dorsal curvature is mostly associated with epispadias (2). Isolated penile curvature is not frequent with an incidence of 0.6 % (3) (level of evidence: 2). The curvature is caused by asymmetry of the cavernous bodies (1,4).

Curvature over 30 degrees is considered clinically significant; curvature over 60 degrees may interfere with satisfactory sexual intercourse in adulthood (5) (level of evidence: 4).

## 6.2 Diagnosis

Diagnosis is made during hypospadias or epispadias repair using an artificial erection (6). The isolated anomaly is usually not recognized until later in childhood because the appearance of the penis is normal. The curvature is only observed during erections.

## 6.3 Treatment

The treatment is surgical. An artificial erection is used to determine the degree of curvature and to check the symmetry after the repair (6).

In hypospadias, chordee related to the tethering of the ventral skin and to the spongiosal pillars is first released. Only in a few cases the penile curvature is caused by a short urethral plate, which should be cut.

To repair the corporeal angulation in the isolated curvature or curvature associated with hypospadias, different techniques of plication of corpora cavernosa (orthoplasty) are used (5).

In epispadias, a combination of complete release of the urethral body from the corpora and a different kind of corporoplasty with or without corporotomy is usually necessary to achieve a straight penis (7,8).

## 6.4 REFERENCES

1. Baskin LS, Duckett JW, Lue TF. Penile curvature. *Urology* 1996;48:347-356.  
[http://www.ncbi.nlm.nih.gov/entrez/query.fcgi?cmd=Retrieve&db=pubmed&dopt=Abstract&list\\_uids=8804484&query\\_hl=66&itool=pubmed\\_docsum](http://www.ncbi.nlm.nih.gov/entrez/query.fcgi?cmd=Retrieve&db=pubmed&dopt=Abstract&list_uids=8804484&query_hl=66&itool=pubmed_docsum)
2. Baka-Jakubiak M. Combined bladder neck, urethral and penile reconstruction in boys with the exstrophy-epispadias complex. *BJU Int* 2000;86:513-518.  
[http://www.ncbi.nlm.nih.gov/entrez/query.fcgi?cmd=Retrieve&db=pubmed&dopt=Abstract&list\\_uids=10971283&query\\_hl=68&itool=pubmed\\_docsum](http://www.ncbi.nlm.nih.gov/entrez/query.fcgi?cmd=Retrieve&db=pubmed&dopt=Abstract&list_uids=10971283&query_hl=68&itool=pubmed_docsum)
3. Yachia D, Beyar M, Aridogan IA, Dascalu S. The incidence of congenital penile curvature. *J Urol* 1993;150:1478-1479.  
[http://www.ncbi.nlm.nih.gov/entrez/query.fcgi?cmd=Retrieve&db=pubmed&dopt=Abstract&list\\_uids=8411431&query\\_hl=70&itool=pubmed\\_docsum](http://www.ncbi.nlm.nih.gov/entrez/query.fcgi?cmd=Retrieve&db=pubmed&dopt=Abstract&list_uids=8411431&query_hl=70&itool=pubmed_docsum)
4. Cendron M. Disorders of the penis and scrotum. In: Gearhart JP, Rink RC, Mouriquand PDE, eds. *Pediatric urology*. Philadelphia: WB Saunders, Philadelphia, 2001, pp. 729-737.
5. Ebbehøj J, Metz P. Congenital penile angulation. *BJU Int* 1987;60:264-266.  
[http://www.ncbi.nlm.nih.gov/entrez/query.fcgi?cmd=Retrieve&db=pubmed&dopt=Abstract&list\\_uids=3676675&query\\_hl=72&itool=pubmed\\_docsum](http://www.ncbi.nlm.nih.gov/entrez/query.fcgi?cmd=Retrieve&db=pubmed&dopt=Abstract&list_uids=3676675&query_hl=72&itool=pubmed_docsum)
6. Gittes RF, McLaughlin AP 3rd. Injection technique to induce penile erection. *Urology* 1974;4:473-474.  
[http://www.ncbi.nlm.nih.gov/entrez/query.fcgi?cmd=Retrieve&db=pubmed&dopt=Abstract&list\\_uids=4418594&query\\_hl=74&itool=pubmed\\_docsum](http://www.ncbi.nlm.nih.gov/entrez/query.fcgi?cmd=Retrieve&db=pubmed&dopt=Abstract&list_uids=4418594&query_hl=74&itool=pubmed_docsum)
7. Woodhouse CRJ. The genitalia in exstrophy and epispadias. In: Gearhart JP, Rink RC, Mouriquand PDE, eds. *Pediatric urology*. Philadelphia: WB Saunders 2001, pp. 557-564.
8. Zaontz MR, Steckler RE, Shortliffe LM, Kogan BA, Baskin L, Tekgul S. Multicenter experience with the Mitchell technique for epispadias repair. *J Urol* 1998;160:172-176.  
[http://www.ncbi.nlm.nih.gov/entrez/query.fcgi?cmd=Retrieve&db=pubmed&dopt=Abstract&list\\_uids=9628644&query\\_hl=76&itool=pubmed\\_docsum](http://www.ncbi.nlm.nih.gov/entrez/query.fcgi?cmd=Retrieve&db=pubmed&dopt=Abstract&list_uids=9628644&query_hl=76&itool=pubmed_docsum)

# 7. VARICOCELE IN CHILDREN AND ADOLESCENTS

## 7.1 Background

Varicocele is defined as an abnormal dilatation of testicular veins in the pampiniformis plexus caused by venous reflux. It is unusual in boys under 10 years of age and becomes more frequent at the beginning of puberty. It is found in 15-20% of adolescents, with a similar incidence during adulthood. It appears mostly on the left side (78-93% of cases). Right-sided varicoceles are least common; they are usually noted only when bilateral varicoceles are present and seldom occur as an isolated finding (1,2).

Varicocele develops during accelerated body growth by a mechanism that is not clearly understood. Varicocele can induce apoptotic pathways because of heat stress, androgen deprivation and accumulation of toxic materials. Severe damage is found in 20% of adolescents affected, with abnormal findings in 46% of affected adolescents. Histological findings are similar in children or adolescents and in infertile men. In 70% of patients with grade II and III varicocele, left testicular volume loss was found. However, studies correlating a



hypoplastic testicle with poor sperm quality have reported controversial results (3,4).

Several authors reported on reversal of testicular growth after varicocelectomy in adolescents (level of evidence: 2) (5,6). However, this may partly be attributable to testicular oedema associated with the division of lymphatic vessels (level of evidence: 2) (7).

In about 20% of adolescents with varicocele, fertility problems will arise (8). The adverse influence of varicocele increases with time. Improvement in sperm parameters has been demonstrated after adolescent varicocelectomy (level of evidence: 1) (3,9).

## 7.2 Diagnosis

Varicocele is mostly asymptomatic, rarely causing pain at this age. It may be noticed by the patient or parents, or discovered by the paediatrician at a routine visit. The diagnosis depends upon the clinical finding of a collection of dilated and tortuous veins in the upright posture; the veins are more pronounced when the patient performs the Valsalva manoeuvre.

Varicocele is classified into 3 grades: Grade I - Valsalva positive (palpable at Valsalva manoeuvre only); Grade II - palpable (palpable without the Valsalva manoeuvre); Grade III - visible (visible at distance) (10). The size of both testicles should be evaluated during palpation to detect a smaller testis.

Venous reflux into the plexus pampiniformis is diagnosed using Doppler colour flow mapping in the supine and upright position (11). Venous reflux detected on ultrasound only is classified as subclinical varicocele. The ultrasound examination includes assessment of the testicular volume to discriminate testicular hypoplasia. In adolescents, a testis that is smaller by more than 2 mL compared to the other testis is considered to be hypoplastic (level of evidence: 4) (1).

In order to assess testicular injury in adolescents with varicocele, supranormal follicle-stimulating hormone (FSH) and luteinizing hormone (LH) responses to the luteinizing hormone-releasing hormone (LHRH) stimulation test are considered reliable, as histopathological testicular changes have been found in these patients (9,12).

## 7.3 Therapy

Surgical intervention is based on ligation or occlusion of the internal spermatic veins. Ligation is performed at different levels:

- inguinal (or subinguinal) microsurgical ligation
- suprainguinal ligation, using open or laparoscopic techniques (13-16).

The advantage of the former is the lower invasiveness of the procedure, while the advantage of the latter is a considerably lower number of veins to be ligated and safety of the incidental division of the internal spermatic artery at the suprainguinal level.

For surgical ligation, some form of optical magnification (microscopic or laparoscopic magnification) should be used because the internal spermatic artery is 0.5 mm in diameter at the level of the internal ring (13-15,17). The recurrence rate is usually less than 10%. Angiographic occlusion is based on retrograde or antegrade sclerotization of the internal spermatic veins (18,19).

Lymphatic-sparing varicocelectomy is preferred to prevent hydrocele formation and testicular hypertrophy development and to achieve a better testicular function according to the LHRH stimulation test (level of evidence: 2, grade A recommendation) (7,13,16,17,20). The methods of choice are subinguinal or inguinal microsurgical (microscopic) repairs, or suprainguinal open or laparoscopic lymphatic-sparing repairs.

Angiographic occlusion of the internal spermatic veins also meets these requirements. However, although this method is less invasive, it appears to have a higher failure rate (level of evidence: 2, grade B recommendation) (1,19).

There is no evidence that treatment of varicocele at paediatric age will offer a better andrological outcome than an operation performed later. The recommended indication criteria for varicocelectomy in children and adolescents are (1,21):

- varicocele associated with a small testis
- additional testicular condition affecting fertility
- bilateral palpable varicocele
- pathological sperm quality (in older adolescents)
- varicocele associated with a supranormal response to LHRH stimulation test
- symptomatic varicocele.

Repair of a large varicocele physically or psychologically causing discomfort may be also considered. Other varicoceles should be followed-up until a reliable sperm analysis can be performed (level of evidence: 4, grade C recommendation).

## 7.4 REFERENCES

1. Kogan SJ. The pediatric varicocele. In: Gearhart JP, Rink RC, Mouriquand PDE, eds. *Pediatric urology*. Philadelphia: WB Saunders, 2001, pp. 763-773.
2. Oster J. Varicocele in children and adolescents. An investigation of the incidence among Danish school children. *Scand J Urol Nephrol*;1971:27-32.  
[http://www.ncbi.nlm.nih.gov/entrez/query.fcgi?cmd=Retrieve&db=pubmed&dopt=Abstract&list\\_uids=5093090&query\\_hl=80&itool=pubmed\\_docsum](http://www.ncbi.nlm.nih.gov/entrez/query.fcgi?cmd=Retrieve&db=pubmed&dopt=Abstract&list_uids=5093090&query_hl=80&itool=pubmed_docsum)
3. Laven JS, Haans LC, Mali WP, te Velde ER, Wensing CJ, Eimers JM. Effects of varicocele treatment in adolescents: a randomized study. *Fertil Steril* 1992;58:756-762.  
[http://www.ncbi.nlm.nih.gov/entrez/query.fcgi?cmd=Retrieve&db=pubmed&dopt=Abstract&list\\_uids=1426322&query\\_hl=84&itool=pubmed\\_docsum](http://www.ncbi.nlm.nih.gov/entrez/query.fcgi?cmd=Retrieve&db=pubmed&dopt=Abstract&list_uids=1426322&query_hl=84&itool=pubmed_docsum)
4. Pinto KJ, Kroovand RL, Jarow JP. Varicocele related testicular atrophy and its predictive effect upon fertility. *J Urol* 1994;152:788-790.  
[http://www.ncbi.nlm.nih.gov/entrez/query.fcgi?cmd=Retrieve&db=pubmed&dopt=Abstract&list\\_uids=8022015&query\\_hl=85&itool=pubmed\\_docsum](http://www.ncbi.nlm.nih.gov/entrez/query.fcgi?cmd=Retrieve&db=pubmed&dopt=Abstract&list_uids=8022015&query_hl=85&itool=pubmed_docsum)
5. Kass EJ, Belman AB. Reversal of testicular growth failure by varicocele ligation. *J Urol* 1987; 137:475-476.  
[http://www.ncbi.nlm.nih.gov/entrez/query.fcgi?cmd=Retrieve&db=pubmed&dopt=Abstract&list\\_uids=3820376&query\\_hl=88&itool=pubmed\\_docsum](http://www.ncbi.nlm.nih.gov/entrez/query.fcgi?cmd=Retrieve&db=pubmed&dopt=Abstract&list_uids=3820376&query_hl=88&itool=pubmed_docsum)
6. Paduch DA, Niedzielski J. Repair versus observation in adolescent varicocele: a prospective study. *J Urol* 1997;158:1128-1132.  
[http://www.ncbi.nlm.nih.gov/entrez/query.fcgi?cmd=Retrieve&db=pubmed&dopt=Abstract&list\\_uids=9258155&query\\_hl=91&itool=pubmed\\_docsum](http://www.ncbi.nlm.nih.gov/entrez/query.fcgi?cmd=Retrieve&db=pubmed&dopt=Abstract&list_uids=9258155&query_hl=91&itool=pubmed_docsum)
7. Kocvara R, Dolezal J, Hampl R, Povysil C, Dvoracek J, Hill M, Dite Z, Stanek Z, Novak K. Division of lymphatic vessels at varicolectomy leads to testicular oedema and decline in testicular function according to the LH-RH analogue stimulation test. *Eur Urol* 2003;43:430-435.  
[http://www.ncbi.nlm.nih.gov/entrez/query.fcgi?cmd=Retrieve&db=pubmed&dopt=Abstract&list\\_uids=12667726&query\\_hl=93&itool=pubmed\\_docsum](http://www.ncbi.nlm.nih.gov/entrez/query.fcgi?cmd=Retrieve&db=pubmed&dopt=Abstract&list_uids=12667726&query_hl=93&itool=pubmed_docsum)
8. World Health Organization. The influence of varicocele on parameters of fertility in a large group of men presenting to infertility clinics. *Fertil Steril* 1992;57:1289-1293.  
[http://www.ncbi.nlm.nih.gov/entrez/query.fcgi?cmd=Retrieve&db=pubmed&dopt=Abstract&list\\_uids=1601152&query\\_hl=95&itool=pubmed\\_docsum](http://www.ncbi.nlm.nih.gov/entrez/query.fcgi?cmd=Retrieve&db=pubmed&dopt=Abstract&list_uids=1601152&query_hl=95&itool=pubmed_docsum)
9. Okuyama A, Nakamura M, Namiki M, Takeyama M, Utsunomiya M, Fujioka H, Itatani H, Matsuda M, Matsumoto K, Sdonoda T. Surgical repair of varicocele at puberty: preventive treatment for fertility improvement. *J Urol* 1988;139:562-564.  
[http://www.ncbi.nlm.nih.gov/entrez/query.fcgi?cmd=Retrieve&db=pubmed&dopt=Abstract&list\\_uids=3343743&query\\_hl=97&itool=pubmed\\_docsum](http://www.ncbi.nlm.nih.gov/entrez/query.fcgi?cmd=Retrieve&db=pubmed&dopt=Abstract&list_uids=3343743&query_hl=97&itool=pubmed_docsum)
10. Dubin L, Amelar RD. Varicocele size and results of varicolectomy in selected subfertile men with a varicocele. *Fertil Steril* 1970;21:606-609.  
[http://www.ncbi.nlm.nih.gov/entrez/query.fcgi?cmd=Retrieve&db=pubmed&dopt=Abstract&list\\_uids=5433164&query\\_hl=99&itool=pubmed\\_docsum](http://www.ncbi.nlm.nih.gov/entrez/query.fcgi?cmd=Retrieve&db=pubmed&dopt=Abstract&list_uids=5433164&query_hl=99&itool=pubmed_docsum)
11. Tasci AI, Resim S, Caskurlu T, Dincel C, Bayraktar Z, Gurbuz G. Color Doppler ultrasonography and spectral analysis of venous flow in diagnosis of varicocele. *Eur Urol* 2001;39:316-321.  
[http://www.ncbi.nlm.nih.gov/entrez/query.fcgi?cmd=Retrieve&db=pubmed&dopt=Abstract&list\\_uids=11275726&query\\_hl=101&itool=pubmed\\_docsum](http://www.ncbi.nlm.nih.gov/entrez/query.fcgi?cmd=Retrieve&db=pubmed&dopt=Abstract&list_uids=11275726&query_hl=101&itool=pubmed_docsum)
12. Aragona F, Ragazzi R, Pozzan GB, De Caro R, Munari PF, Milani C, Glazel GP. Correlation of testicular volume, histology and LHRH test in adolescents with idiopathic varicocele. *Eur Urol* 1994;26:61-66.  
[http://www.ncbi.nlm.nih.gov/entrez/query.fcgi?cmd=Retrieve&db=pubmed&dopt=Abstract&list\\_uids=7925532&query\\_hl=103&itool=pubmed\\_docsum](http://www.ncbi.nlm.nih.gov/entrez/query.fcgi?cmd=Retrieve&db=pubmed&dopt=Abstract&list_uids=7925532&query_hl=103&itool=pubmed_docsum)
13. Goldstein M, Gilbert BR, Dicker AP, Dwosh J, Gnecco C. Microsurgical inguinal varicolectomy with delivery of the testis: an artery and lymphatic sparing technique. *J Urol* 1992;148:1808-1811.  
[http://www.ncbi.nlm.nih.gov/entrez/query.fcgi?cmd=Retrieve&db=pubmed&dopt=Abstract&list\\_uids=1433614&query\\_hl=106&itool=pubmed\\_docsum](http://www.ncbi.nlm.nih.gov/entrez/query.fcgi?cmd=Retrieve&db=pubmed&dopt=Abstract&list_uids=1433614&query_hl=106&itool=pubmed_docsum)
14. Hopps CV, Lemer ML, Schlegel PN, Goldstein M. Intraoperative varicocele anatomy: a microscopic study of the inguinal versus subinguinal approach. *J Urol* 2003;170:2366-2370.  
[http://www.ncbi.nlm.nih.gov/entrez/query.fcgi?cmd=Retrieve&db=pubmed&dopt=Abstract&list\\_uids=14634418&query\\_hl=108&itool=pubmed\\_docsum](http://www.ncbi.nlm.nih.gov/entrez/query.fcgi?cmd=Retrieve&db=pubmed&dopt=Abstract&list_uids=14634418&query_hl=108&itool=pubmed_docsum)

15. Kocvara R, Dvoracek J, Sedlacek J, Dite Z, Novak K. Lymphatic-sparing laparoscopic varicocelectomy: a microsurgical repair. *J Urol* 2005;173:1751-1754.  
[http://www.ncbi.nlm.nih.gov/entrez/query.fcgi?cmd=Retrieve&db=pubmed&dopt=Abstract&list\\_uids=15821575&query\\_hl=110&itool=pubmed\\_docsum](http://www.ncbi.nlm.nih.gov/entrez/query.fcgi?cmd=Retrieve&db=pubmed&dopt=Abstract&list_uids=15821575&query_hl=110&itool=pubmed_docsum)
16. Riccabona M, Oswald J, Koen M, Lusuardi L, Radmayr C, Bartsch G. Optimizing the operative treatment of boys with varicocele: sequential comparison of 4 techniques. *J Urol* 2003;169:666-668.  
[http://www.ncbi.nlm.nih.gov/entrez/query.fcgi?cmd=Retrieve&db=pubmed&dopt=Abstract&list\\_uids=12544340&query\\_hl=113&itool=pubmed\\_docsum](http://www.ncbi.nlm.nih.gov/entrez/query.fcgi?cmd=Retrieve&db=pubmed&dopt=Abstract&list_uids=12544340&query_hl=113&itool=pubmed_docsum)
17. Marmar J, Benoff S. New scientific information related to varicoceles. (Editorial.) *J Urol* 2003;170:2371-2373.  
[http://www.ncbi.nlm.nih.gov/entrez/query.fcgi?cmd=Retrieve&db=pubmed&dopt=Abstract&list\\_uids=14634419&query\\_hl=115&itool=pubmed\\_docsum](http://www.ncbi.nlm.nih.gov/entrez/query.fcgi?cmd=Retrieve&db=pubmed&dopt=Abstract&list_uids=14634419&query_hl=115&itool=pubmed_docsum)
18. Mazzoni G, Minucci S, Gentile V. Recurrent varicocele: role of antegrade sclerotherapy as first choice treatment. *Eur Urol* 2002;41:614-618; discussion 618.  
[http://www.ncbi.nlm.nih.gov/entrez/query.fcgi?cmd=Retrieve&db=pubmed&dopt=Abstract&list\\_uids=12074778&query\\_hl=117&itool=pubmed\\_docsum](http://www.ncbi.nlm.nih.gov/entrez/query.fcgi?cmd=Retrieve&db=pubmed&dopt=Abstract&list_uids=12074778&query_hl=117&itool=pubmed_docsum)
19. Thon WF, Gall H, Danz B, Bahren W, Sigmund G. Percutaneous sclerotherapy of idiopathic varicocele in childhood: a preliminary report. *J Urol* 1989;141:913-915.  
[http://www.ncbi.nlm.nih.gov/entrez/query.fcgi?cmd=Retrieve&db=pubmed&dopt=Abstract&list\\_uids=2926889&query\\_hl=119&itool=pubmed\\_docsum](http://www.ncbi.nlm.nih.gov/entrez/query.fcgi?cmd=Retrieve&db=pubmed&dopt=Abstract&list_uids=2926889&query_hl=119&itool=pubmed_docsum)
20. Minevich E, Wacksman J, Lewis AG, Sheldon CA. Inguinal microsurgical varicocelectomy in the adolescent: technique and preliminary results. *J Urol* 1998;159:1022-1024.  
[http://www.ncbi.nlm.nih.gov/entrez/query.fcgi?cmd=Retrieve&db=pubmed&dopt=Abstract&list\\_uids=9474223&query\\_hl=121&itool=pubmed\\_docsum](http://www.ncbi.nlm.nih.gov/entrez/query.fcgi?cmd=Retrieve&db=pubmed&dopt=Abstract&list_uids=9474223&query_hl=121&itool=pubmed_docsum)
21. Kass EJ, Reitelman C. The adolescent with a varicocele: who needs repair? *Probl Urol* 1994;8:507-517.

## 8. MICROPENIS

### 8.1 Background

Micropenis is a small but otherwise normally formed penis with a stretched length of less than 2.5 SD below the mean (1-3).

Besides an idiopathic micropenis, two major causes of abnormal hormonal stimulation have been identified:

- hypogonadotropic hypogonadism (due to an inadequate secretion of GnRH)
- hypergonadotropic hypogonadism (due to failure of the testes to produce testosterone).

### 8.2 Diagnosis

The penis is measured on the dorsal aspect, while stretching the penis, from the pubic symphysis to the tip of the glans (1). The corpora cavernosa are palpated, the scrotum is often small, and the testes may be small and descended. Micropenis should be distinguished from buried and webbed penis, which is usually of normal size.

The initial evaluation has to define whether the aetiology of the micropenis is central (hypothalamic/pituitary) or testicular. A paediatric endocrinology work-up has to be carried out immediately. Karyotyping is mandatory in all patients with a micropenis.

Endocrine testicular function is assessed (baseline and stimulated testosterone, LH and FSH serum levels). Stimulated hormone levels may also give an idea of the growth potential of the penis. In patients with non-palpable testes and hypogonadotropic hypogonadism, laparoscopy should be carried out to confirm vanishing testes syndrome or intra-abdominal undescended hypoplastic testes. This investigation can be delayed until the age of 1 year (2).

### 8.3 Treatment

Pituitary or testicular insufficiency are treated by the paediatric endocrinologist. In patients with testicular failure and proven androgen sensitivity, androgen therapy is recommended during childhood and at puberty to stimulate the growth of the penis (level of evidence: 2, grade B recommendation) (4-7). In the presence of androgen insensitivity, good outcome of sexual function is questioned and gender conversion can be considered (8-10).

## 8.4 REFERENCES

1. Feldman KW, Smith DW. Fetal phallic growth and penile standards for newborn male infants. *J Pediatr* 1975;86:395-398.  
[http://www.ncbi.nlm.nih.gov/entrez/query.fcgi?cmd=Retrieve&db=pubmed&dopt=Abstract&list\\_uids=1113226&query\\_hl=158&itool=pubmed\\_docsum](http://www.ncbi.nlm.nih.gov/entrez/query.fcgi?cmd=Retrieve&db=pubmed&dopt=Abstract&list_uids=1113226&query_hl=158&itool=pubmed_docsum)
2. Aaronson IA. Micropenis; medical and surgical implications. *J Urol* 1994;152:4-14.
3. Gonzales JR. Micropenis. *AUA Update Series* 1983;2:1.
4. Burstein S, Grumbach MM, Kaplan SL. Early determination of androgen-responsiveness is important in the management of micropenis. *Lancet* 1979;2:983-986.  
[http://www.ncbi.nlm.nih.gov/entrez/query.fcgi?cmd=Retrieve&db=pubmed&dopt=Abstract&list\\_uids=91775&query\\_hl=163&itool=pubmed\\_docsum](http://www.ncbi.nlm.nih.gov/entrez/query.fcgi?cmd=Retrieve&db=pubmed&dopt=Abstract&list_uids=91775&query_hl=163&itool=pubmed_docsum)
5. Choi SK, Han SW, Kim DH, de Lignieres B. Transdermal dihydrotestosterone therapy and its effects on patients with micropenis. *J Urol* 1993;150:657-660.  
[http://www.ncbi.nlm.nih.gov/entrez/query.fcgi?cmd=Retrieve&db=pubmed&dopt=Abstract&list\\_uids=8326617&query\\_hl=166&itool=pubmed\\_docsum](http://www.ncbi.nlm.nih.gov/entrez/query.fcgi?cmd=Retrieve&db=pubmed&dopt=Abstract&list_uids=8326617&query_hl=166&itool=pubmed_docsum)
6. Diamond M. Pediatric management of ambiguous and traumatized genitalia. *J Urol* 1999;162:1021-1028.  
[http://www.ncbi.nlm.nih.gov/entrez/query.fcgi?cmd=Retrieve&db=pubmed&dopt=Abstract&list\\_uids=10458424&query\\_hl=169&itool=pubmed\\_docsum](http://www.ncbi.nlm.nih.gov/entrez/query.fcgi?cmd=Retrieve&db=pubmed&dopt=Abstract&list_uids=10458424&query_hl=169&itool=pubmed_docsum)
7. Bin-Abbas B, Conte FA, Grumbach MM, Kaplan SL. Congenital hypogonadotropic hypogonadism and micropenis: effect of testosterone treatment on adult penile size. Why sex reversal is not indicated. *J Pediatr* 1999;134:579-583.  
[http://www.ncbi.nlm.nih.gov/entrez/query.fcgi?cmd=Retrieve&db=pubmed&dopt=Abstract&list\\_uids=10228293&query\\_hl=7&itool=pubmed\\_docsum](http://www.ncbi.nlm.nih.gov/entrez/query.fcgi?cmd=Retrieve&db=pubmed&dopt=Abstract&list_uids=10228293&query_hl=7&itool=pubmed_docsum)
8. Calikoglu AS. Should boys with micropenis be reared as girls? *J Pediatr* 1999;134:537-538.  
[http://www.ncbi.nlm.nih.gov/entrez/query.fcgi?cmd=Retrieve&db=pubmed&dopt=Abstract&list\\_uids=10228285&query\\_hl=10&itool=pubmed\\_docsum](http://www.ncbi.nlm.nih.gov/entrez/query.fcgi?cmd=Retrieve&db=pubmed&dopt=Abstract&list_uids=10228285&query_hl=10&itool=pubmed_docsum)
9. Reilly JM, Woodhouse CR. Small penis and the male sexual role. *J Urol* 1989;142:569-571.  
[http://www.ncbi.nlm.nih.gov/entrez/query.fcgi?cmd=Retrieve&db=pubmed&dopt=Abstract&list\\_uids=2746779&query\\_hl=15&itool=pubmed\\_docsum](http://www.ncbi.nlm.nih.gov/entrez/query.fcgi?cmd=Retrieve&db=pubmed&dopt=Abstract&list_uids=2746779&query_hl=15&itool=pubmed_docsum)
10. Husmann DA. The androgen insensitive micropenis: long-term follow-up into adulthood. *J Pediatr Endocrinol Metab* 2004;17:1037-1041.  
[http://www.ncbi.nlm.nih.gov/entrez/query.fcgi?cmd=Retrieve&db=pubmed&dopt=Abstract&list\\_uids=15379413&query\\_hl=17&itool=pubmed\\_docsum](http://www.ncbi.nlm.nih.gov/entrez/query.fcgi?cmd=Retrieve&db=pubmed&dopt=Abstract&list_uids=15379413&query_hl=17&itool=pubmed_docsum)

## 9. VOIDING DYSFUNCTION

### 9.1 Background

Voiding dysfunction is the term used to group together functional incontinence problems in children. After any possible underlying uropathy or neuropathy has been excluded, a problem of incontinence in children is grouped into the category of 'voiding dysfunction'. The only exception is solitary night-time wetting, which is known as enuresis.

Although exact data are unavailable, it is clear that the incidence of voiding dysfunction is increasing. The changes in toilet training and toilet habits associated with a modern lifestyle have been blamed for the increase in incidence, but with little evidence. Rather, it is that modern life and higher hygiene standards have probably resulted in more attention being drawn to incontinence problems, so that an increase in prevalence can probably be attributed to an increased awareness.

### 9.2 Definition

Voiding dysfunction is a condition that presents with lower urinary tract symptoms (LUTS), including urge, incontinence, weak stream, hesitancy, frequency and urinary tract infections, but without overt uropathy or neuropathy.

Normal bladder storage and voiding involves low pressure and adequate bladder volume filling. This is then followed by a continuous detrusor contraction that results in complete bladder emptying, associated with an adequate relaxation of the sphincter complex.

Normal urine storage by the bladder and evacuation are controlled by a complex interaction between the spinal cord, brain stem, midbrain and higher cortical structures, associated with a complex integration of

sympathetic, parasympathetic and somatic innervations.

It is understandable that this complex control mechanism is likely to be susceptible to developing different types of dysfunction. Various functional disorders of the detrusor-sphincter complex may occur during the sophisticated course of the early development of normal mechanisms of micturition control. Voiding dysfunction is therefore thought to be the expression of incomplete or delayed maturation of the bladder sphincter complex.

Normal daytime control of bladder function matures between 2 and 3 years of age, while night-time control is normally achieved between 3 and 7 years of age.

There are two main groups of voiding dysfunction, namely filling-phase dysfunctions and voiding-phase dysfunctions.

#### *9.2.1 Filling-phase dysfunctions*

In filling-phase dysfunctions, the detrusor can be overactive, as in overactive bladder or urge syndrome, or underactive, as in underactive or highly compliant detrusor (formerly known as 'lazy bladder').

#### *9.2.2 Voiding-phase (emptying) dysfunctions*

In voiding-phase (emptying) dysfunctions, interference with the sphincter and pelvic floor during detrusor contraction is the main dysfunction. Different degrees of dysfunction are described depending on the strength of interference with the sphincter and pelvic floor. Weak interference results in staccato voiding, while stronger interference results in interrupted voiding and straining, due to an inability to relax during voiding.

Bladder sphincter dysfunction is often associated with bowel dysfunction such as obstipation and soiling. Sometimes, secondary anatomical changes are observed, such as trabeculation, diverticulae and vesicoureteral reflux.

### **9.3 Diagnosis**

A non-invasive screening, consisting of history-taking, clinical examination, uroflow, ultrasound and voiding diary, is essential to reach a diagnosis.

In the paediatric age group, where the history is taken from both the parents and child together, a structured approach is recommended using a questionnaire. Many signs and symptoms related to voiding and wetting will be unknown to the parents and should be specifically requested, using the questionnaire as a checklist. A voiding diary is mandatory to determine the child's voiding frequency and voided volumes as well as the child's drinking habits. History-taking should also include assessment of bowel function.

Upon clinical examination, genital inspection and observation of the lumbosacral spine and the lower extremities is necessary to exclude obvious uropathy and neuropathy. Uroflow with post-void residual evaluates the emptying ability while upper urinary tract ultrasound screens for secondary anatomical changes. A voiding diary provides information about storage function and incontinence frequency, while a pad test can help to quantify the urine loss.

In the case of therapy resistance to initial treatment, or in the case of former failed treatment, re-evaluation is warranted and further video-urodynamic studies may be considered. Sometimes, there are minor, underlying, urological or neurological problems, which can only be suspected using video-urodynamics.

In the case of anatomical problems, such as urethral valve problems, syringocoeles, congenital obstructive posterior urethral membrane (COPUM) or Moormann's ring, it may be necessary to perform further cystoscopy with treatment. If neuropathic disease is suspected, MRI of the lumbosacral spine and medulla can help to exclude tethered cord, lipoma or other rare conditions.

Psychological screening may be useful for children or families with major psychological problems associated with the voiding dysfunction.

### **9.4 Treatment**

Treatment of voiding dysfunction consists of lower urinary tract rehabilitation, mostly referred to as urotherapy. Urotherapy means non-surgical, non-pharmacological treatment of lower urinary tract (LUT) function. It is a very broad field, incorporating many therapies used by urotherapists and other healthcare professionals. Urotherapy can be divided into standard therapy and specific interventions.

#### *9.4.1 Standard therapy*

Standard urotherapy is non-interventional. It includes the following components:

- information and demystification, which includes explanation about normal LUT function and in what way a particular child deviates from normal function
- instruction about what to do about the problem, i.e. regular voiding habits, sound voiding posture, avoiding holding manoeuvres, etc.
- lifestyle advice, regarding fluid intake, prevention of constipation, etc.

- registration of symptoms and voiding habits using bladder diaries or frequency-volume charts
- support and encouragement via regular follow-up by the caregiver.

Most studies on the effect of urotherapy programmes are retrospective. Independent of the elements of a urotherapy programme, a success rate of 80% has been described. The evidence level is low as most studies are retrospective and non-controlled.

#### 9.4.2 Specific interventions

As well as urotherapy, there are some specific interventions, including physiotherapy (e.g. pelvic floor exercises), biofeedback, alarm therapy and neurostimulation. Although good results with these treatment modalities have been reported, there have been no randomized controlled treatment trials (RCTs), so that the level of evidence is low.

In some cases, pharmacotherapy may be added. Antispasmodics and anticholinergics have been shown to be efficient in the treatment. Even for these pharmacological interventions, no RCTs have been published, so that the level of evidence is low. Alpha-blocking agents are sporadically used, but their efficiency remains to be proven.

However, the evidence currently available suggests that a good outcome is simply related to the fact that training is being given and attention is being paid to the incontinence problem rather than a specific kind and/or amount of training is required.

## 9.5 REFERENCES

1. Van Gool JD, Hjalmas K, Tamminen-Mobius T, Olbing H. Historical clues to the complex of dysfunctional voiding, urinary tract infection and vesicoureteral reflux. The International Reflux Study in Children. *J Urol* 1992;148:1699-1702.  
[http://www.ncbi.nlm.nih.gov/entrez/query.fcgi?cmd=Retrieve&db=pubmed&dopt=Abstract&list\\_uids=1433591&query\\_hl=177&itool=pubmed\\_docsum](http://www.ncbi.nlm.nih.gov/entrez/query.fcgi?cmd=Retrieve&db=pubmed&dopt=Abstract&list_uids=1433591&query_hl=177&itool=pubmed_docsum)
2. Hellstrom AL, Hanson E, Hansson S, Hjalmas K, Jodal U. Micturition habits and incontinence in 7-year-old Swedish school entrants. *Eur J Pediatr* 1990;149:434-437.  
[http://www.ncbi.nlm.nih.gov/entrez/query.fcgi?cmd=Retrieve&db=pubmed&dopt=Abstract&list\\_uids=2332015&query\\_hl=179&itool=pubmed\\_docsum](http://www.ncbi.nlm.nih.gov/entrez/query.fcgi?cmd=Retrieve&db=pubmed&dopt=Abstract&list_uids=2332015&query_hl=179&itool=pubmed_docsum)
3. Hellstrom AL, Hjalmas K, Jodal U. Rehabilitation of the dysfunctional bladder in children: method and 3-year followup. *J Urol* 1987;138:847-849.  
[http://www.ncbi.nlm.nih.gov/entrez/query.fcgi?cmd=Retrieve&db=pubmed&dopt=Abstract&list\\_uids=3656544&query\\_hl=181&itool=pubmed\\_docsum](http://www.ncbi.nlm.nih.gov/entrez/query.fcgi?cmd=Retrieve&db=pubmed&dopt=Abstract&list_uids=3656544&query_hl=181&itool=pubmed_docsum)
4. Hellstrom AL. Urotherapy in children with dysfunctional bladder. *Scand J Urol Nephrol Suppl* 1992;141:106-107.  
[http://www.ncbi.nlm.nih.gov/entrez/query.fcgi?cmd=Retrieve&db=pubmed&dopt=Abstract&list\\_uids=1609245&query\\_hl=183&itool=pubmed\\_docsum](http://www.ncbi.nlm.nih.gov/entrez/query.fcgi?cmd=Retrieve&db=pubmed&dopt=Abstract&list_uids=1609245&query_hl=183&itool=pubmed_docsum)
5. Hoebeke P, Vande Walle J, Theunis M, De Paepe H, Oosterlinck W, Renson C. Outpatient pelvic-floor therapy in girls with daytime incontinence and dysfunctional voiding. *Urology* 1996;48:923-927.  
[http://www.ncbi.nlm.nih.gov/entrez/query.fcgi?cmd=Retrieve&db=pubmed&dopt=Abstract&list\\_uids=8973679&query\\_hl=186&itool=pubmed\\_docsum](http://www.ncbi.nlm.nih.gov/entrez/query.fcgi?cmd=Retrieve&db=pubmed&dopt=Abstract&list_uids=8973679&query_hl=186&itool=pubmed_docsum)
6. Hoebeke PB, Vande Walle J. The pharmacology of paediatric incontinence. *BJU Int* 2000;86:581-589.  
[http://www.ncbi.nlm.nih.gov/entrez/query.fcgi?cmd=Retrieve&db=pubmed&dopt=Abstract&list\\_uids=10971299&query\\_hl=188&itool=pubmed\\_docsum](http://www.ncbi.nlm.nih.gov/entrez/query.fcgi?cmd=Retrieve&db=pubmed&dopt=Abstract&list_uids=10971299&query_hl=188&itool=pubmed_docsum)
7. McKenna PH, Herndon CD, Connery S, Ferrer FA. Pelvic floor muscle retraining for pediatric voiding dysfunction using interactive computer games. *J Urol* 1999;162:1056-1062.  
[http://www.ncbi.nlm.nih.gov/entrez/query.fcgi?cmd=Retrieve&db=pubmed&dopt=Abstract&list\\_uids=10458431&query\\_hl=190&itool=pubmed\\_docsum](http://www.ncbi.nlm.nih.gov/entrez/query.fcgi?cmd=Retrieve&db=pubmed&dopt=Abstract&list_uids=10458431&query_hl=190&itool=pubmed_docsum)
8. Shei Dei Yang S, Wang CC. Outpatient biofeedback relaxation of the pelvic floor in treating pediatric dysfunctional voiding: a short-course program is effective. *Urol Int* 2005;74:118-122.  
[http://www.ncbi.nlm.nih.gov/entrez/query.fcgi?cmd=Retrieve&db=pubmed&dopt=Abstract&list\\_uids=15756062&query\\_hl=192&itool=pubmed\\_docsum](http://www.ncbi.nlm.nih.gov/entrez/query.fcgi?cmd=Retrieve&db=pubmed&dopt=Abstract&list_uids=15756062&query_hl=192&itool=pubmed_docsum)
9. Vijverberg MA, Elzinga-Plomp A, Messer AP, van Gool JD, de Jong TP. Bladder rehabilitation, the effect of a cognitive training programme on urge incontinence. *Eur Urol* 1997;31:68-72.  
[http://www.ncbi.nlm.nih.gov/entrez/query.fcgi?cmd=Retrieve&db=pubmed&dopt=Abstract&list\\_uids=9032538&query\\_hl=194&itool=pubmed\\_docsum](http://www.ncbi.nlm.nih.gov/entrez/query.fcgi?cmd=Retrieve&db=pubmed&dopt=Abstract&list_uids=9032538&query_hl=194&itool=pubmed_docsum)

10. Akbal C, Genc Y, Burgu B, Ozden E, Tekgul S. Dysfunctional voiding and incontinence scoring system: quantitative evaluation of incontinence symptoms in pediatric population. *J Urol* 2005;173:969-973. [http://www.ncbi.nlm.nih.gov/entrez/query.fcgi?cmd=Retrieve&db=pubmed&dopt=Abstract&list\\_uids=15711352&query\\_hl=196&itool=pubmed\\_docsum](http://www.ncbi.nlm.nih.gov/entrez/query.fcgi?cmd=Retrieve&db=pubmed&dopt=Abstract&list_uids=15711352&query_hl=196&itool=pubmed_docsum)

## 10. ENURESIS (MONOSYMPOMATIC)

### 10.1 Background

Bedwetting is a frequent symptom in children. Bedwetting as a single symptom is called *enuresis*. With a prevalence of 5-10% at 7 years of age, it is one of the most prevalent conditions in childhood. With a spontaneous yearly cure rate of 15%, it is considered to be a relatively benign condition (1,2).

However, 7 out of 100 children wetting the bed at age 7 will take this condition into adulthood. As it is a stressful condition which puts a high psychological burden on children, resulting in low self-esteem, treatment is advised from the age of 6-7 years onwards. Spontaneous cure rates at a younger age are high, making treatment unnecessary. Furthermore, the child's mental status, family expectations, social issues and cultural background need to be considered before treatment can be started.

### 10.2 Definition

Enuresis is the condition describing the symptom of incontinence during night. Any wetting during sleep above the age of 5 years is enuresis. However, most importantly, there is a single symptom only. Thorough history-taking, excluding any other daytime symptoms, is mandatory before diagnosing enuresis. Any associated urinary tract symptoms makes the condition a form of voiding dysfunction (3).

The condition is described as 'primary' when the symptom has existed always and the patient has not been dry for a period longer than 6 months. The condition is described as 'secondary', when there has been a symptom-free interval of 6 months. Genetically, enuresis is a complex and heterogeneous disorder. Loci have been described on chromosomes 12, 13 and 22 (3).

In the pathophysiology, three factors play an important role:

- high night-time urine output
- night-time low bladder capacity or increased detrusor activity
- arousal disorder.

Due to an imbalance between night-time urine output and night-time bladder capacity, the bladder can become easily full at night and the child will either wake up to empty the bladder or will void during sleep if there is a lack of arousal from sleep (1-3).

### 10.3 Diagnosis

The diagnosis is obtained by history-taking. When bedwetting is really the only symptom, no further investigations are needed. A voiding diary, registering the daytime bladder function and the night-time urine output will help to guide the treatment. Weighing diapers (nappies) in the morning and adding the volume of the morning void gives an estimate of the night-time urine production. Registering the daytime bladder capacity gives an estimate of bladder capacity compared to normal values for age (4).

In most children, bedwetting is a familial problem, with most affected children found to have a history of bedwetting within the family.

### 10.4 Treatment

Before using alarm treatment or medication, simple therapeutic interventions should be considered.

#### 10.4.1 Supportive treatment measures

Explaining the condition to the child and his parents helps to demystify the problem. Eating and drinking habits should be reviewed, stressing normal fluid intake during day and reducing fluid intake in the hours before sleep. Keeping a chart depicting wet and dry nights has been shown to be successful.

Counselling, provision of information, positive reinforcement and increasing (and supporting) motivation of the child should be introduced first. There is a high level of evidence showing that supportive treatment is more successful than doing nothing, though the cure rate is not significantly high. However, supportive therapy as initial management carries a high grade of recommendation (4).

If supportive measures have no success, further treatment modalities must be considered, of which pharmacological treatment and alarm treatment are the two most important.

#### 10.4.2 Alarm treatment

Alarm treatment obtains the highest level of recommendation (grade A recommendation). It is the best form of treatment for arousal disorder. Initial success rates of 80% with low relapse rates are realistic, especially when night-time diuresis is not too high and bladder capacity is not too low (5).

#### 10.4.3 Medication

In case of high night-time diuresis, success rates of 70% can be obtained with desmopressine (DDAVP), 10-40 µg nasal spray or 200-400 µg tablets. However, relapse rates are higher after DDAVP discontinuation (4). In the case of a small bladder capacity, treatments with antispasmodics or anticholinergics are possible (4). Imipramine, which has been popular in the treatment of enuresis, obtains only a moderate response rate of 50% and has a high relapse rate. Furthermore, cardiotoxicity and death with overdose are described. Its use should therefore be discouraged.

### 10.5 REFERENCES

1. Lackgren G, Hjalmas K, van Gool J, von Gontard A, de Gennaro M, Lottmann H, Terho P. Nocturnal enuresis: a suggestion for a European treatment strategy. *Acta Paediatr* 1999;88:679-690.  
[http://www.ncbi.nlm.nih.gov/entrez/query.fcgi?cmd=Retrieve&db=pubmed&dopt=Abstract&list\\_uids=10419258&query\\_hl=1&itool=pubmed\\_docsum](http://www.ncbi.nlm.nih.gov/entrez/query.fcgi?cmd=Retrieve&db=pubmed&dopt=Abstract&list_uids=10419258&query_hl=1&itool=pubmed_docsum)
2. Norgaard JP, van Gool JD, Hjalmas K, Djurhuus JC, Hellstrom AL. Standardization and definitions in lower urinary tract dysfunction in children. International Children's Continence Society. *Br J Urol* 1998;81(Suppl 3):1-16.  
[http://www.ncbi.nlm.nih.gov/entrez/query.fcgi?cmd=Retrieve&db=pubmed&dopt=Abstract&list\\_uids=9634012&query\\_hl=3&itool=pubmed\\_docsum](http://www.ncbi.nlm.nih.gov/entrez/query.fcgi?cmd=Retrieve&db=pubmed&dopt=Abstract&list_uids=9634012&query_hl=3&itool=pubmed_docsum)
3. Neveus T, Lackgren G, Tuvemo T, Hetta J, Hjalmas K, Stenberg A. Enuresis - background and treatment. *Scand J Urol Nephrol* 2000;206(Suppl):1-44.  
[http://www.ncbi.nlm.nih.gov/entrez/query.fcgi?cmd=Retrieve&db=pubmed&dopt=Abstract&list\\_uids=11196246&query\\_hl=5&itool=pubmed\\_docsum](http://www.ncbi.nlm.nih.gov/entrez/query.fcgi?cmd=Retrieve&db=pubmed&dopt=Abstract&list_uids=11196246&query_hl=5&itool=pubmed_docsum)
4. Hjalmas K, Arnold T, Bower W, Caione P, Chiozza LM, von Gontard A, Han SW, Husman DA, Kawauchi A, Lackgren G, Lottmann H, Mark S, Rittig S, Robson L, Walle JV, Yeung CK. Nocturnal enuresis: an international evidence based management strategy. *J Urol* 2004;171:2545-2561.  
[http://www.ncbi.nlm.nih.gov/entrez/query.fcgi?cmd=Retrieve&db=pubmed&dopt=Abstract&list\\_uids=15118418&query\\_hl=7&itool=pubmed\\_docsum](http://www.ncbi.nlm.nih.gov/entrez/query.fcgi?cmd=Retrieve&db=pubmed&dopt=Abstract&list_uids=15118418&query_hl=7&itool=pubmed_docsum)
5. Glazener CM, Evans JH, Peto RE. Alarm interventions for nocturnal enuresis in children. *Cochrane Database Syst Rev* 2005;(2):CD002911.  
[http://www.ncbi.nlm.nih.gov/entrez/query.fcgi?cmd=Retrieve&db=pubmed&dopt=Abstract&list\\_uids=15846643&query\\_hl=9&itool=pubmed\\_docsum](http://www.ncbi.nlm.nih.gov/entrez/query.fcgi?cmd=Retrieve&db=pubmed&dopt=Abstract&list_uids=15846643&query_hl=9&itool=pubmed_docsum)

## 11. MANAGEMENT OF NEUROGENIC BLADDER IN CHILDREN

### 11.1 Background

The management of neurogenic bladder sphincter dysfunction in children has undergone major changes over the years. Although diapers, permanent catheters, external appliances, crede manoeuvre and various forms of urinary diversion have been acceptable treatment methods, these are now reserved for only a small number of resistant patients. The introduction of clean self-intermittent catheterization (CIC) revolutionized the management of children with neurogenic bladder. Not only has it made conservative management a very successful treatment option, but it has also made surgical creation of continent reservoirs a very effective treatment alternative with a good outcome for quality of life and kidney protection (1-3).

Neurogenic bladder in children with myelodysplasia presents with various patterns of detrusor-sphincter dysfunction within a wide range of severity. About 15% of neonates with myelodysplasia have no signs of neurourological dysfunction at birth. However, there is a high chance of progressive changes in the dynamics of neurological lesions with time. Even babies with normal neurourological function at birth have a 1 in 3 risk of developing either detrusor sphincter dyssynergia or denervation by the time they reach puberty. At birth, the majority of patients have normal upper urinary tracts, but nearly 60% of them develop upper tract deterioration due to infections, bladder changes and reflux (4-7).

As our understanding of urodynamic studies has evolved, it has allowed us to understand the nature



and severity of problems and manage these patients in a more rational and individualized manner. Despite the remarkable changes of the last quarter of the 20th century, the main goals of treatment have remained the same, i.e. prevention of urinary tract deterioration and achievement of continence at an appropriate age.

## 11.2 Definition

Neurogenic bladder sphincter dysfunction can develop as a result of a lesion at any level in the nervous system, including the cerebral cortex, spinal cord or the peripheral nervous system.

The most common presentation is at birth with myelodysplasia. The term myelodysplasia includes a group of developmental anomalies that result from defects in neural tube closure. Lesions may include spina bifida occulta, meningocele, lipomyelomeningocele, or myelomeningocele. Myelomeningocele is by far the most common defect seen and the most detrimental. Traumatic and neoplastic spinal lesions of the cord are less frequent in children. Additionally, different growth rates between the vertebral bodies and the elongating spinal cord can introduce a dynamic factor to the lesion. Scar tissue surrounding the cord at the site of meningocele closure can tether the cord during growth.

In occult myelodysplasia the lesions are not overt and often occur with no obvious signs of neurological lesion, but in many patients, a cutaneous abnormality overlies the lower spine. Total or partial sacral agenesis is a rare congenital anomaly that involves absence of part or all of one or more sacral vertebrae. This anomaly can be part of the caudal regression syndrome and has to be considered in any child presenting with anorectal malformation (ARM). Cerebral palsy patients may also present with varying degrees of voiding dysfunction usually in the form of uninhibited bladder contractions, voiding dysfunction often due to spasticity of the pelvic floor and sphincter complex and wetting.

Bladder sphincter dysfunction is poorly correlated with the type and spinal level of the neurological lesion.

## 11.3 Classification

The purpose of any classification system is to facilitate the understanding and management of the underlying pathology. There are various systems of classification of neurogenic bladder.

Most systems of classification were formulated primarily to describe those types of dysfunction secondary to neurological disease or injury. Such systems are based on the localization of the neurological lesion and findings of the neuro-urological examination. These classifications have been of more value in adults, in whom neurogenic lesions are usually due to trauma and more readily identifiable.

In children, the spinal level and extent of congenital lesion are poorly correlated with the clinical outcome. Urodynamic and functional classifications have therefore been more practical for defining the extent of the pathology and planning treatment in children.

The bladder and sphincter are two units working in harmony to make a single functional unit. The initial approach should be to evaluate the state of each unit and define the pattern of bladder dysfunction. According to the nature of the neurological deficit, the bladder and sphincter may be in either an overactive or an inactive state:

- the bladder may be overactive with increased contractions, low capacity and compliance or inactive with no effective contractions.
- the outlet (urethra and sphincter) may be independently overactive causing functional obstruction or paralyzed with no resistance to urinary flow.
- these conditions may present in different combinations.

This is mainly a classification based on urodynamic findings. The understanding of the pathophysiology of disorders is essential to plan a rational treatment plan for each individual patient. In meningomyelocele, most patients will present with hyperreflexive detrusor and dyssynergic sphincter, which is a dangerous combination as pressure is built up and the upper tract is threatened.

## 11.4 Urodynamic studies

Urodynamic studies enable the clinician to observe lower urinary tract function and its deviations from normal. Since the treatment plan mainly depends upon a good understanding of the underlying problem in the lower urinary tract, a well-performed urodynamic study is mandatory in the evaluation of each child with neurogenic bladder.

As the bony level often does not correspond with the neurological defect present, and as the effect of the lesion on bladder function cannot be entirely determined by radiographic studies or physical examination, the information gained from a urodynamic study is priceless. A urodynamic study also provides the clinician with information about the response of the vesicourethral unit to therapy, as demonstrated by improvement or deterioration in follow-up.

It is important to determine several urodynamic parameters, including:

- bladder capacity
- intravesical-filling pressure

- intravesical pressure at the moment of urethral leakage
- presence or absence of reflex detrusor activity
- competence of the internal and external sphincteric mechanisms
- degree of coordination of the detrusor and sphincteric mechanisms
- voiding pattern
- postvoiding residual urine volume.

#### 11.4.1 Method of urodynamic study

There is very little comparative data evaluating the complexity and invasiveness of urodynamic testing for neurogenic bladders in children.

#### 11.4.2 Uroflowmetry

As uroflowmetry is the least invasive of all urodynamic tests, it can be used as an initial screening tool. It provides an objective way of assessing the efficiency of voiding, and together with an ultrasonographic examination, residual urine volume can also be determined. Unlike in children with non-neurogenic voiding dysfunction, uroflowmetry will rarely be used as a single investigational tool in children with neurogenic bladders, as it does not provide information for bladder storage, yet it may be very practical to monitor emptying in the follow-up. The main limitation of a urodynamic study is the need for the child to be old enough to follow instructions and void on request.

The recording of pelvic floor or abdominal skeletal muscle activity by electromyography (EMG) during uroflowmetry can be used to evaluate coordination between detrusor and the sphincter. As it is a non-invasive test, combined uroflowmetry and EMG may be very useful in evaluating sphincter activity during voiding. The absence of an indwelling catheter during this study eliminates false-positive findings caused by the catheter (8-10) (level of evidence: 4).

#### 11.4.3 Cystometry

Although moderately invasive and dependent on a cooperative child, cystometry in children provides valuable information regarding detrusor contractility and compliance. The amount of information obtained from each study is related to the degree of interest and care given to the test.

It is important to be aware of the alterations in filling and emptying detrusor pressures as the infusion rates change during cystometry. Slow fill cystometry (filling rate < 10 mL/min) is recommended by the International Children's Continence Society (ICCS) for use in children (11). However, it has been suggested that the infusion rate should be set according to the child's predicted capacity, based on age and divided by 10 (12).

Several clinical studies using conventional artificial fill cystometry to evaluate neurogenic bladder in children have reported that conventional cystometry provides useful information for diagnosis and follow-up of children with neurogenic bladder (13-18). All the studies were retrospective clinical series and lacked comparison with natural fill cystometry, so that the grade of recommendation for an artificial cystometry in children with neurogenic bladder is not high (level of evidence: 4). Additionally, there is evidence suggesting that natural bladder behaviour is altered during regular artificial filling cystometry (19,20).

However, conventional cystometry in infants is useful for predicting future deterioration. Urodynamic parameters, such as low capacity and compliance and high leak-point pressures, are poor prognostic factors for future deterioration. Resolution of reflux is less likely to happen in such bladders (13,18,20) (level of evidence: 4).

During natural fill cystometry, the bladder is allowed to fill naturally and the recording of bladder and abdominal pressure is done using microtransducer catheters. Theoretically, this allows investigation of bladder function in near-physiological conditions. Studies on natural fill cystometry in children report similar results to those of studies done in adults. Natural fill cystometry gives a lower detrusor pressure rise during filling and lower voided volumes with higher voiding pressures. The incidence of bladder overactivity is higher with natural filling cystometry when compared to conventional artificial filling cystometry (19,21,22).

Although only a few studies on natural fill cystometry have been done in children with neurogenic bladder, the results suggest that natural fill cystometry detects new findings compared with diagnoses delivered by conventional cystometry (19) (level of evidence: 3). However, the comparison between natural fill and artificial fill cystometry has not been performed against a gold standard, so making it difficult to conclude which study is a true reflection of natural bladder behaviour. Findings in the non-neurogenic adult population have questioned the reliability of natural fill cystometry, as natural fill cystometry has shown a high incidence of bladder overactivity in totally normal asymptomatic volunteers (23).

The main disadvantage of natural fill cystometry is that it is labour-intensive and time consuming. Especially in children, the recording of events is difficult and there is an increased risk of artefacts, which makes interpretation of the huge amount of data even more difficult. Natural fill cystometry still remains a new

technique in the paediatric population. More data needs to be gathered in a standard way before it can be widely accepted (10).

## **11.5 Management**

The medical care of children with myelodysplasia with a neurogenic bladder requires constant observation and adaptation to new problems. In the first years of life, the kidneys are highly susceptible to back-pressure and infection. During this period of life, the emphasis is on documenting the pattern of neurogenic detrusor-sphincter dysfunction and assessing the potential for functional obstruction and vesicoureteric reflux (VUR).

### *11.5.1 Investigations*

An abdominal ultrasound obtained as soon as possible after birth will detect hydronephrosis or other upper genitourinary tract pathology. Following ultrasound, a voiding cystourethrogram should be obtained to evaluate the lower urinary tract. Measurement of residual urine during both ultrasound and cystography should also be done. These studies provide a baseline for the appearance of the upper and lower urinary tracts, can facilitate the diagnosis of hydronephrosis or VUR, and can help identify children at risk for upper genitourinary tract deterioration and impairment of renal function.

A urodynamic evaluation can be done after some weeks and needs to be repeated at regular intervals, in combination with evaluation of the upper tracts (24-26) (level of evidence: 3, grade B recommendation).

### *11.5.2 Early management with clean intermittent catheterization (CIC)*

Overwhelming experience gained over the years with early management of neurogenic bladder in infants has led to a consensus that children do not have upper tract deterioration when managed early with CIC and anticholinergic medication. Clean intermittent catheterization should be started soon after birth in all babies, especially in those with signs of possible outlet obstruction (24,27-35) (level of evidence: 2, grade B recommendation).

The early initiation of CIC in the newborn period, makes it easier for parents to master the procedure and for children to accept it as they grow older (36,37).

Early management results in less upper tract changes, but also better bladder protection and lower incontinence rates. It has been suggested that increased bladder pressures due to detrusor sphincter dyssynergia cause secondary changes of the bladder wall. These fibroproliferative changes in the bladder wall may cause further loss of elasticity and compliance, resulting in a small non-compliant bladder with progressively elevated pressures.

Early institution of CIC and anticholinergic drugs may prevent this in some patients (2,35,38) (level of evidence: 3). The retrospective evaluation of patients has also shown that significantly less augmentations were required in patients with an early start to CIC (31,32) (level of evidence: 4).

### *11.5.3 Medical therapy*

At present, oxybutynin, tolterodine, trospium and propiverine are the most frequently used drugs. Most of the studies have been done on oxybutynine. Although the clinical outcome is imposing, the level of evidence is low since there are no controlled studies (38,39-42) (level of evidence: 3, grade B recommendation).

The use of medication in children with neurogenic bladder to facilitate emptying has not been well studied in the literature. A few studies investigating the use of  $\alpha$ -adrenergic blockade in children with neurogenic bladder have reported a good response rate, but the studies lacked controls and long-term follow-up is warranted (43) (level of evidence: 4, grade C recommendation).

#### *11.5.3.1 Botulinum toxin injections*

In neurogenic bladders, which are refractory to anticholinergics and remain in a small-capacity, high-pressure state, a novel treatment alternative is injection of botulinum toxin into the detrusor. Initial promising results in adults have initiated its use in children.

So far, studies of the clinical effect of botulinum toxin in children have been open trials and there is a lack of prospective controlled trials. However, injection of botulinum toxin in therapy-resistant bladders appears to be an effective and safe treatment alternative. The treatment seems to be more effective on bladders with a more active component. Stiff bladders without an active component are unlikely to respond to botulinum toxin (44-47). Currently, it is unclear how many times this treatment can be repeated. In adults repetitive treatment has been found to be safe (level of evidence: 3).

#### *11.5.4 Management of bowel incontinence*

Children with neurogenic bladder have disturbances of bowel function as well as urinary function. Bowel incontinence in these children is frequently unpredictable. It is related to the turnover rate of faecal material in the anal area after evacuation, the degree of intactness of sacral cord sensation and motor function, and reflex

reactivity of the external anal sphincter (48).

Bowel incontinence is managed most commonly with mild laxatives, such as mineral oil, combined with enemas to facilitate removal of bowel contents. A regular and efficient bowel emptying regimen is often necessary to maintain faecal continence and may have to be started at a very young age. With antegrade or retrograde enemas, most of these children will have decreased constipation problems and may attain some degree of faecal continence (49-53) (level of evidence: 3).

Biofeedback training programmes to strengthen the external anal sphincter have not been shown to be more effective than a conventional bowel management programme in achieving faecal continence (54). Electrostimulation of the bowel may also offer a variable improvement in some patients (55) (level of evidence: 3).

#### 11.5.5 *Urinary tract infection*

Urinary tract infections (UTIs) are common in children with neurogenic bladders. In the absence of reflux, UTIs should be treated symptomatically. There is strong evidence for not prescribing antibiotics to patients who have bacteriuria but no clinical symptoms. Although bacteriuria is seen in more than half of children on CIC, patients who are asymptomatic do not need treatment (56-58) (level of evidence: 3). Patients with VUR should usually be placed on prophylactic antibiotics to reduce the incidence of pyelonephritis, which can potentially lead to renal damage (59-60).

#### 11.5.6 *Sexuality*

Sexuality, while not an issue in childhood, becomes progressively more important as the patient gets older. This issue has historically been overlooked in individuals with myelodysplasia. However, patients with myelodysplasia have sexual encounters. Studies indicate that at least 15-20% of males are capable of fathering children and 70% of females can conceive and carry a pregnancy to term. Counselling patients regarding sexual development is therefore important in early adolescence.

#### 11.5.7 *Bladder augmentation*

Children with a good response to anticholinergic treatment and an overactive sphincter may be continent between catheterizations. Bladder pressure and development of the upper urinary tract will determine whether additional treatment is necessary.

Therapy-resistant overactivity of the detrusor, or small capacity and poor compliance, will usually need to be treated by bladder augmentation. A simple bladder augmentation using intestine may be carried out if there is any bladder tissue, a competent sphincter and/or bladder neck, and an urethra that can be catheterized. Stomach is rarely used as an augmenting patch because of the associated complications, but it is the only available intestinal segment for patients with impaired renal function (61). Ileal or colonic patches are used frequently for augmenting the bladder, with either intestinal segment appearing to be equally useful. Despite some advantages (e.g. avoiding mucus, decreased malignancy rate and less complications), alternative urothelium-preserving techniques, such as autoaugmentation and seromuscular cystoplasty, have not proven to be as successful as standard augmentation with intestine (62).

#### 11.5.8 *Bladder outlet procedures*

Children with detrusor overactivity, but with underactive sphincters, will be better for protecting their upper tracts. However, they will be severely incontinent. Initial treatment is CIC (as it may reduce the degree of incontinence and offers a much better control over UTIs) with anticholinergic drugs. At a later age, the outlet resistance will be increased in order to render them continent. No medical treatment available has been validated to increase bladder outlet resistance. Alpha-receptor stimulation of the bladder neck has not been very effective (63-68).

When conservative measures fail, surgical procedures need to be considered for maintaining continence. Although a simple augmentation is sufficient for most low-capacity, high-pressure bladders, augmentation with additional bladder outlet procedures is required when both the bladder and outlet are deficient. Bladder outlet procedures include bladder neck reconstruction or other forms of urethral reconstruction.

There are various procedures used on the bladder neck to increase resistance, but all these procedures may complicate transurethral catheterization. Augmentation with surgical closure of the bladder neck may be required primarily, or as a secondary procedure in certain rare clinical situations. In this situation, a continent stoma will be required. However, most surgeons prefer to leave the bladder neck and urethra patent as a safety precaution.

#### 11.5.9 *Continent stoma*

Augmentation with an additional continent stoma is utilized primarily following failure of previous bladder outlet surgery. It is also advisable when an inability to catheterize transurethrally is likely. An abdominal wall continent stoma may be particularly beneficial to the wheelchair-bound spina bifida patient, who may often have difficulty

with urethral catheterization or who is dependent on others to catheterize the bladder. For continence with augmentation and an abdominal wall stoma, an adequate bladder outlet mechanism is essential to maintain continence.

#### 11.5.10 Total bladder replacement

Total bladder replacement in anticipation of normal voiding in children is very rare, as there are infrequent indications for a total cystectomy, with preservation of the bladder outlet and a competent urethral sphincter. This type of bladder replacement is much more common in adult urological reconstruction. Any type of major bladder and bladder outlet construction should be performed in centres with sufficient experience of the surgical technique and with experienced healthcare personnel to carry out post-operative follow-up (69-71).

#### 11.5.11 Lifelong follow-up of neurogenic bladder patients

Neurogenic bladder patients require lifelong supervision and monitoring of renal function is extremely important. Periodic investigation of upper tract changes, renal function and bladder status is mandatory. Repeat urodynamic tests are therefore needed more frequently (every year) in younger children and less frequently in older children. From the urological viewpoint, a repeat urodynamic study is warranted when the patient has a change in symptoms or undergoes any neurosurgical procedure. In the case of any apparent changes in the upper and lower urinary tract or changes in neurological symptoms, a more detailed examination including urodynamics and spinal magnetic resonance imaging is indicated. Renal failure can progress slowly or occur with startling speed in these children.

## 11.6 REFERENCES

1. Bauer SB. The management of the myelodysplastic child: a paradigm shift. *BJU Int* 2003;92(Suppl 1):23-28.  
[http://www.ncbi.nlm.nih.gov/entrez/query.fcgi?cmd=Retrieve&db=pubmed&dopt=Abstract&list\\_uids=12969005&query\\_hl=1&itool=pubmed\\_docsum](http://www.ncbi.nlm.nih.gov/entrez/query.fcgi?cmd=Retrieve&db=pubmed&dopt=Abstract&list_uids=12969005&query_hl=1&itool=pubmed_docsum)
2. Retik AB, Perlmutter AD, Gross RE. Cutaneous ureteroileostomy in children. *N Eng J Med* 1967;277:217-222.  
[http://www.ncbi.nlm.nih.gov/entrez/query.fcgi?cmd=Retrieve&db=pubmed&dopt=Abstract&list\\_uids=4226464&query\\_hl=3&itool=pubmed\\_docsum](http://www.ncbi.nlm.nih.gov/entrez/query.fcgi?cmd=Retrieve&db=pubmed&dopt=Abstract&list_uids=4226464&query_hl=3&itool=pubmed_docsum)
3. Lapedes J, Diokno AC, Silber SJ, Lowe BS. Clean, intermittent self-catheterization in the treatment of urinary tract disease. 1972. *J Urol* 2002;167:1131-1133.  
[http://www.ncbi.nlm.nih.gov/entrez/query.fcgi?cmd=Retrieve&db=pubmed&dopt=Abstract&list\\_uids=11905887&query\\_hl=5&itool=pubmed\\_docsum](http://www.ncbi.nlm.nih.gov/entrez/query.fcgi?cmd=Retrieve&db=pubmed&dopt=Abstract&list_uids=11905887&query_hl=5&itool=pubmed_docsum)
4. Bauer SB. The management of spina bifida from birth onwards. In: Whitaker RH, Woodard JR, eds. *Paediatric urology*. London: Butterworths, 1985, pp. 87-112.
5. Bauer SB. Early evaluation and management of children with spina bifida. In: King LR, ed. *Urologic surgery in neonates and young infants*. Philadelphia: WB Saunders, 1988, pp. 252-264.
6. Wilcock AR, Emery JL. Deformities of the renal tract in children with meningomyelocele and hydrocephalus, compared with those of children showing no such deformities. *Br J Urol* 1970;42:152-157.  
[http://www.ncbi.nlm.nih.gov/entrez/query.fcgi?cmd=Retrieve&db=pubmed&dopt=Abstract&list\\_uids=5420153&query\\_hl=8&itool=pubmed\\_docsum](http://www.ncbi.nlm.nih.gov/entrez/query.fcgi?cmd=Retrieve&db=pubmed&dopt=Abstract&list_uids=5420153&query_hl=8&itool=pubmed_docsum)
7. Hunt GM, Whitaker RH. The pattern of congenital renal anomalies associated with neural-tube defects. *Dev Med Child Neurol* 1987;29:91-95.  
[http://www.ncbi.nlm.nih.gov/entrez/query.fcgi?cmd=Retrieve&db=pubmed&dopt=Abstract&list\\_uids=3556803&query\\_hl=11&itool=pubmed\\_docsum](http://www.ncbi.nlm.nih.gov/entrez/query.fcgi?cmd=Retrieve&db=pubmed&dopt=Abstract&list_uids=3556803&query_hl=11&itool=pubmed_docsum)
8. Aoki H, Adachi M, Banya Y, Sakuma Y, Seo K, Kubo T, Ohori T, Takagane H, Suzuki Y. [Evaluation of neurogenic bladder in patients with spinal cord injury using a CMG.EMG study and CMG.UFM.EMG study.] *Hinyokika Kyo* 1985;31:937-948. [Japanese]  
[http://www.ncbi.nlm.nih.gov/entrez/query.fcgi?cmd=Retrieve&db=pubmed&dopt=Abstract&list\\_uids=4061211&query\\_hl=13&itool=pubmed\\_docsum](http://www.ncbi.nlm.nih.gov/entrez/query.fcgi?cmd=Retrieve&db=pubmed&dopt=Abstract&list_uids=4061211&query_hl=13&itool=pubmed_docsum)
9. Casado JS, Virseda Chamorro M, Leva Vallejo M, Fernandez Lucas C, Aristizabal Agudelo JM, de la Fuente Trabado M. [Urodynamic assessment of the voiding phase in childhood.] *Arch Esp Urol* 2002;55:177-189. [Spanish]  
[http://www.ncbi.nlm.nih.gov/entrez/query.fcgi?cmd=Retrieve&db=pubmed&dopt=Abstract&list\\_uids=12014050&query\\_hl=15&itool=pubmed\\_docsum](http://www.ncbi.nlm.nih.gov/entrez/query.fcgi?cmd=Retrieve&db=pubmed&dopt=Abstract&list_uids=12014050&query_hl=15&itool=pubmed_docsum)
10. Wen JG, Yeung CK, Djurhuus JC. Cystometry techniques in female infants and children. *Int Urogynecol J Pelvic Floor Dysfunct* 2000;11:103-112.  
[http://www.ncbi.nlm.nih.gov/entrez/query.fcgi?cmd=Retrieve&db=pubmed&dopt=Abstract&list\\_uids=10805268&query\\_hl=17&itool=pubmed\\_docsum](http://www.ncbi.nlm.nih.gov/entrez/query.fcgi?cmd=Retrieve&db=pubmed&dopt=Abstract&list_uids=10805268&query_hl=17&itool=pubmed_docsum)

11. Norgaard JP, van Gool JD, Hjalmas K, Djurhuus JC, Hellstrom AL. Standardization and definitions in lower urinary tract dysfunction in children. International Children's Continence Society. *Br J Urol* 1998;81(Suppl 3):1-16.  
[http://www.ncbi.nlm.nih.gov/entrez/query.fcgi?cmd=Retrieve&db=pubmed&dopt=Abstract&list\\_uids=9634012&query hl=20&itool=pubmed\\_docsum](http://www.ncbi.nlm.nih.gov/entrez/query.fcgi?cmd=Retrieve&db=pubmed&dopt=Abstract&list_uids=9634012&query hl=20&itool=pubmed_docsum)
12. Bauer SB. Pediatric urodynamics: lower tract. In: O'Donnell B, Koff SA, eds. *Pediatric urology*. Oxford: Butterworth-Heinemann, 1998, pp. 125-151.
13. Tanikaze S, Sugita Y. [Cystometric examination for neurogenic bladder of neonates and infants.] *Hinyokika Kiyō* 1991;37:1403-1405. [Japanese]  
[http://www.ncbi.nlm.nih.gov/entrez/query.fcgi?cmd=Retrieve&db=pubmed&dopt=Abstract&list\\_uids=1767767&query hl=23&itool=pubmed\\_docsum](http://www.ncbi.nlm.nih.gov/entrez/query.fcgi?cmd=Retrieve&db=pubmed&dopt=Abstract&list_uids=1767767&query hl=23&itool=pubmed_docsum)
14. Zoller G, Schoner W, Ringert RH. Pre- and postoperative urodynamic findings in children with tethered spinal cord syndrome. *Eur Urol* 1991;19:139-141.  
[http://www.ncbi.nlm.nih.gov/entrez/query.fcgi?cmd=Retrieve&db=pubmed&dopt=Abstract&list\\_uids=2022217&query hl=25&itool=pubmed\\_docsum](http://www.ncbi.nlm.nih.gov/entrez/query.fcgi?cmd=Retrieve&db=pubmed&dopt=Abstract&list_uids=2022217&query hl=25&itool=pubmed_docsum)
15. Ghoniem GM, Roach MB, Lewis VH, Harmon EP. The value of leak pressure and bladder compliance in the urodynamic evaluation of meningomyelocele patients. *J Urol* 1990;144:1440-1442.  
[http://www.ncbi.nlm.nih.gov/entrez/query.fcgi?cmd=Retrieve&db=pubmed&dopt=Abstract&list\\_uids=2231938&query hl=27&itool=pubmed\\_docsum](http://www.ncbi.nlm.nih.gov/entrez/query.fcgi?cmd=Retrieve&db=pubmed&dopt=Abstract&list_uids=2231938&query hl=27&itool=pubmed_docsum)
16. Ghoniem GM, Shoukry MS, Hassouna ME. Detrusor properties in myelomeningocele patients: in vitro study. *J Urol* 1998;159:2193-2196.  
[http://www.ncbi.nlm.nih.gov/entrez/query.fcgi?cmd=Retrieve&db=pubmed&dopt=Abstract&list\\_uids=9598568&query hl=30&itool=pubmed\\_docsum](http://www.ncbi.nlm.nih.gov/entrez/query.fcgi?cmd=Retrieve&db=pubmed&dopt=Abstract&list_uids=9598568&query hl=30&itool=pubmed_docsum)
17. Palmer LS, Richards I, Kaplan WE. Age related bladder capacity and bladder capacity growth in children with myelomeningocele. *J Urol* 1997;158:1261-1264.  
[http://www.ncbi.nlm.nih.gov/entrez/query.fcgi?cmd=Retrieve&db=pubmed&dopt=Abstract&list\\_uids=9258190&query hl=32&itool=pubmed\\_docsum](http://www.ncbi.nlm.nih.gov/entrez/query.fcgi?cmd=Retrieve&db=pubmed&dopt=Abstract&list_uids=9258190&query hl=32&itool=pubmed_docsum)
18. Agarwal SK, McLorie GA, Grewal D, Joyner BD, Bagli DJ, Khoury AE. Urodynamic correlates of resolution of reflux in meningomyelocele patients. *J Urol* 1997;158:580-582.  
[http://www.ncbi.nlm.nih.gov/entrez/query.fcgi?cmd=Retrieve&db=pubmed&dopt=Abstract&list\\_uids=9224367&query hl=34&itool=pubmed\\_docsum](http://www.ncbi.nlm.nih.gov/entrez/query.fcgi?cmd=Retrieve&db=pubmed&dopt=Abstract&list_uids=9224367&query hl=34&itool=pubmed_docsum)
19. Zermann DH, Lindner H, Huschke T, Schubert J. Diagnostic value of natural fill cystometry in neurogenic bladder in children. *Eur Urol* 1997;32:223-228.  
[http://www.ncbi.nlm.nih.gov/entrez/query.fcgi?cmd=Retrieve&db=pubmed&dopt=Abstract&list\\_uids=9286658&query hl=36&itool=pubmed\\_docsum](http://www.ncbi.nlm.nih.gov/entrez/query.fcgi?cmd=Retrieve&db=pubmed&dopt=Abstract&list_uids=9286658&query hl=36&itool=pubmed_docsum)
20. Webb RJ, Griffiths CJ, Ramsden PD, Neal DE. Measurement of voiding pressures on ambulatory monitoring: comparison with conventional cystometry. *Br J Urol* 1990;65:152-154.  
[http://www.ncbi.nlm.nih.gov/entrez/query.fcgi?cmd=Retrieve&db=pubmed&dopt=Abstract&list\\_uids=2317646&query hl=38&itool=pubmed\\_docsum](http://www.ncbi.nlm.nih.gov/entrez/query.fcgi?cmd=Retrieve&db=pubmed&dopt=Abstract&list_uids=2317646&query hl=38&itool=pubmed_docsum)
21. McInerney PD, Vanner TF, Harris SA, Stephenson TP. Ambulatory urodynamics. *Br J Urol* 1991;67:272-274.  
[http://www.ncbi.nlm.nih.gov/entrez/query.fcgi?cmd=Retrieve&db=pubmed&dopt=Abstract&list\\_uids=2021814&query hl=42&itool=pubmed\\_docsum](http://www.ncbi.nlm.nih.gov/entrez/query.fcgi?cmd=Retrieve&db=pubmed&dopt=Abstract&list_uids=2021814&query hl=42&itool=pubmed_docsum)
22. Yeung CK, Godley ML, Duffy PG, Ransley PG. Natural filling cystometry in infants and children. *Br J Urol* 1995;75:531-537.  
[http://www.ncbi.nlm.nih.gov/entrez/query.fcgi?cmd=Retrieve&db=pubmed&dopt=Abstract&list\\_uids=7788266&query hl=45&itool=pubmed\\_docsum](http://www.ncbi.nlm.nih.gov/entrez/query.fcgi?cmd=Retrieve&db=pubmed&dopt=Abstract&list_uids=7788266&query hl=45&itool=pubmed_docsum)
23. Swithinbank LV, James M, Shepherd A, Abrams P. Role of ambulatory urodynamic monitoring in clinical urological practice. *Neurourol Urodyn* 1999;18:215-222.  
[http://www.ncbi.nlm.nih.gov/entrez/query.fcgi?cmd=Retrieve&db=pubmed&dopt=Abstract&list\\_uids=10338442&query hl=47&itool=pubmed\\_docsum](http://www.ncbi.nlm.nih.gov/entrez/query.fcgi?cmd=Retrieve&db=pubmed&dopt=Abstract&list_uids=10338442&query hl=47&itool=pubmed_docsum)
24. McGuire EJ, Woodside JR, Borden TA, Weiss RM. Prognostic value of urodynamic testing in myelodysplastic patients. 1981. *J Urol* 2002;167:1049-1053.  
[http://www.ncbi.nlm.nih.gov/entrez/query.fcgi?cmd=Retrieve&db=pubmed&dopt=Abstract&list\\_uids=11905876&query hl=49&itool=pubmed\\_docsum](http://www.ncbi.nlm.nih.gov/entrez/query.fcgi?cmd=Retrieve&db=pubmed&dopt=Abstract&list_uids=11905876&query hl=49&itool=pubmed_docsum)
25. Sillen U, Hansson E, Hermansson G, Hjalmas, Jacobsson B, Jodal U. Development of the urodynamic pattern in infants with myelomeningocele. *Br J Urol* 1996;78:596-601.  
[http://www.ncbi.nlm.nih.gov/entrez/query.fcgi?cmd=Retrieve&db=pubmed&dopt=Abstract&list\\_uids=8944517&query hl=51&itool=pubmed\\_docsum](http://www.ncbi.nlm.nih.gov/entrez/query.fcgi?cmd=Retrieve&db=pubmed&dopt=Abstract&list_uids=8944517&query hl=51&itool=pubmed_docsum)

26. Tarcan T, Bauer S, Olmedo E, Khoshbin S, Kelly M, Darbey M. Long-term follow-up of newborns with myelodysplasia and normal urodynamic findings: is follow-up necessary? *J Urol* 2001;165:564-567. [http://www.ncbi.nlm.nih.gov/entrez/query.fcgi?cmd=Retrieve&db=pubmed&dopt=Abstract&list\\_uids=11176436&query\\_hl=54&itool=pubmed\\_docsum](http://www.ncbi.nlm.nih.gov/entrez/query.fcgi?cmd=Retrieve&db=pubmed&dopt=Abstract&list_uids=11176436&query_hl=54&itool=pubmed_docsum)
27. Kasabian NG, Bauer SB, Dyro FM, Colodny AH, Mandell J, Retik AB. The prophylactic value of clean intermittent catheterization and anticholinergic medication in newborns and infants with myelodysplasia at risk of developing urinary tract deterioration. *Am J Dis Child* 1992;146:840-843. [http://www.ncbi.nlm.nih.gov/entrez/query.fcgi?cmd=Retrieve&db=pubmed&dopt=Abstract&list\\_uids=1496955&query\\_hl=56&itool=pubmed\\_docsum](http://www.ncbi.nlm.nih.gov/entrez/query.fcgi?cmd=Retrieve&db=pubmed&dopt=Abstract&list_uids=1496955&query_hl=56&itool=pubmed_docsum)
28. Wang SC, McGuire EJ, Bloom DA. Urethral dilatation in the management of urological complications of myelodysplasia. *J Urol* 1989;142:1054-1055. [http://www.ncbi.nlm.nih.gov/entrez/query.fcgi?cmd=Retrieve&db=pubmed&dopt=Abstract&list\\_uids=2795730&query\\_hl=58&itool=pubmed\\_docsum](http://www.ncbi.nlm.nih.gov/entrez/query.fcgi?cmd=Retrieve&db=pubmed&dopt=Abstract&list_uids=2795730&query_hl=58&itool=pubmed_docsum)
29. Lin-Dyken DC, Wolraich ML, Hawtrey CE, Doja MS. Follow-up of clean intermittent catheterization for children with neurogenic bladders. *Urology* 1992;40:525-529. [http://www.ncbi.nlm.nih.gov/entrez/query.fcgi?cmd=Retrieve&db=pubmed&dopt=Abstract&list\\_uids=1466106&query\\_hl=60&itool=pubmed\\_docsum](http://www.ncbi.nlm.nih.gov/entrez/query.fcgi?cmd=Retrieve&db=pubmed&dopt=Abstract&list_uids=1466106&query_hl=60&itool=pubmed_docsum)
30. Kaufman AM, Ritchey ML, Roberts AC, Rudy DC, McGuire EJ. Decreased bladder compliance in patients with myelomeningocele treated with radiological observation. *J Urol* 1996;156:2031-2033. [http://www.ncbi.nlm.nih.gov/entrez/query.fcgi?cmd=Retrieve&db=pubmed&dopt=Abstract&list\\_uids=8965337&query\\_hl=62&itool=pubmed\\_docsum](http://www.ncbi.nlm.nih.gov/entrez/query.fcgi?cmd=Retrieve&db=pubmed&dopt=Abstract&list_uids=8965337&query_hl=62&itool=pubmed_docsum)
31. Wu HY, Baskin LS, Kogan BA. Neurogenic bladder dysfunction due to myelomeningocele: neonatal versus childhood treatment. *J Urol* 1997;157:2295-2297. [http://www.ncbi.nlm.nih.gov/entrez/query.fcgi?cmd=Retrieve&db=pubmed&dopt=Abstract&list\\_uids=9146656&query\\_hl=64&itool=pubmed\\_docsum](http://www.ncbi.nlm.nih.gov/entrez/query.fcgi?cmd=Retrieve&db=pubmed&dopt=Abstract&list_uids=9146656&query_hl=64&itool=pubmed_docsum)
32. Kaefer M, Pabby A, Kelly M, Darbey M, Bauer SB. Improved bladder function after prophylactic treatment of the high risk neurogenic bladder in newborns with myelomeningocele. *J Urol* 1999;162:1068-1071. [http://www.ncbi.nlm.nih.gov/entrez/query.fcgi?cmd=Retrieve&db=pubmed&dopt=Abstract&list\\_uids=10458433&query\\_hl=66&itool=pubmed\\_docsum](http://www.ncbi.nlm.nih.gov/entrez/query.fcgi?cmd=Retrieve&db=pubmed&dopt=Abstract&list_uids=10458433&query_hl=66&itool=pubmed_docsum)
33. van Gool JD, Dik P, de Jong TP. Bladder-sphincter dysfunction in myelomeningocele. *Eur J Pediatr* 2001;160:414-420. [http://www.ncbi.nlm.nih.gov/entrez/query.fcgi?cmd=Retrieve&db=pubmed&dopt=Abstract&list\\_uids=11475578&query\\_hl=68&itool=pubmed\\_docsum](http://www.ncbi.nlm.nih.gov/entrez/query.fcgi?cmd=Retrieve&db=pubmed&dopt=Abstract&list_uids=11475578&query_hl=68&itool=pubmed_docsum)
34. Bauer SB. The argument for early assessment and treatment of infants with spina bifida. *Dialogues in Pediatric Urology* 2000;23:2-3.
35. Park JM. Early reduction of mechanical load of the bladder improves compliance: experimental and clinical observations. *Dialogues in Pediatric Urology* 2000;23:6-7.
36. Lindehall B, Moller A, Hjalmas K, Jodal U. Long-term intermittent catheterization: the experience of teenagers and young adults with myelomeningocele. *J Urol* 1994;152:187-189. [http://www.ncbi.nlm.nih.gov/entrez/query.fcgi?cmd=Retrieve&db=pubmed&dopt=Abstract&list\\_uids=8201663&query\\_hl=72&itool=pubmed\\_docsum](http://www.ncbi.nlm.nih.gov/entrez/query.fcgi?cmd=Retrieve&db=pubmed&dopt=Abstract&list_uids=8201663&query_hl=72&itool=pubmed_docsum)
37. Joseph DB, Bauer SB, Colodny AH, Mandell J, Retik AB. Clean intermittent catheterization in infants with neurogenic bladder. *Pediatrics* 1989;84:72-82. [http://www.ncbi.nlm.nih.gov/entrez/query.fcgi?cmd=Retrieve&db=pubmed&dopt=Abstract&list\\_uids=2740179&query\\_hl=74&itool=pubmed\\_docsum](http://www.ncbi.nlm.nih.gov/entrez/query.fcgi?cmd=Retrieve&db=pubmed&dopt=Abstract&list_uids=2740179&query_hl=74&itool=pubmed_docsum)
38. Baskin LS, Kogan BA, Benard F. Treatment of infants with neurogenic bladder dysfunction using anticholinergic drugs and intermittent catheterization. *Br J Urol* 1990;66:532-534. [http://www.ncbi.nlm.nih.gov/entrez/query.fcgi?cmd=Retrieve&db=pubmed&dopt=Abstract&list\\_uids=2249125&query\\_hl=79&itool=pubmed\\_docsum](http://www.ncbi.nlm.nih.gov/entrez/query.fcgi?cmd=Retrieve&db=pubmed&dopt=Abstract&list_uids=2249125&query_hl=79&itool=pubmed_docsum)
39. Connor JP, Betrus G, Fleming P, Perlmutter AD, Reitelman C. Early cystometrograms can predict the response to intravesical instillation of oxybutynin chloride in myelomeningocele patients. *J Urol* 1994;151:1045-1047. [http://www.ncbi.nlm.nih.gov/entrez/query.fcgi?cmd=Retrieve&db=pubmed&dopt=Abstract&list\\_uids=8126787&query\\_hl=81&itool=pubmed\\_docsum](http://www.ncbi.nlm.nih.gov/entrez/query.fcgi?cmd=Retrieve&db=pubmed&dopt=Abstract&list_uids=8126787&query_hl=81&itool=pubmed_docsum)
40. Goessel C, Knispel HH, Fiedler U, Harle B, Steffen-Wilke K, Miller K. Urodynamic effects of oral oxybutynin chloride in children with myelomeningocele and detrusor hyperreflexia. *Urology* 1998;51:94-98. [http://www.ncbi.nlm.nih.gov/entrez/query.fcgi?cmd=Retrieve&db=pubmed&dopt=Abstract&list\\_uids=9457296&query\\_hl=83&itool=pubmed\\_docsum](http://www.ncbi.nlm.nih.gov/entrez/query.fcgi?cmd=Retrieve&db=pubmed&dopt=Abstract&list_uids=9457296&query_hl=83&itool=pubmed_docsum)

41. Haferkamp A, Staehler G, Gerner HJ, Dorsam J. Dosage escalation of intravesical oxybutynin in the treatment of neurogenic bladder patients. *Spinal Cord* 2000;38:250-254.  
[http://www.ncbi.nlm.nih.gov/entrez/query.fcgi?cmd=Retrieve&db=pubmed&dopt=Abstract&list\\_uids=10822396&query\\_hl=85&itool=pubmed\\_docsum](http://www.ncbi.nlm.nih.gov/entrez/query.fcgi?cmd=Retrieve&db=pubmed&dopt=Abstract&list_uids=10822396&query_hl=85&itool=pubmed_docsum)
42. Ferrara P, D'Aleo CM, Tarquini E, Salvatore S, Salvaggio E. Side-effects of oral or intravesical oxybutynin chloride in children with spina bifida. *BJU Int* 2001;87:674-678.  
[http://www.ncbi.nlm.nih.gov/entrez/query.fcgi?cmd=Retrieve&db=pubmed&dopt=Abstract&list\\_uids=11350411&query\\_hl=87&itool=pubmed\\_docsum](http://www.ncbi.nlm.nih.gov/entrez/query.fcgi?cmd=Retrieve&db=pubmed&dopt=Abstract&list_uids=11350411&query_hl=87&itool=pubmed_docsum)
43. Austin PF, Homsy YL, Masel JL, Cain MP, Casale AJ, Rink RC. Alpha-adrenergic blockade in children with neuropathic and nonneuropathic voiding dysfunction. *J Urol* 1999;162:1064-1067.  
[http://www.ncbi.nlm.nih.gov/entrez/query.fcgi?cmd=Retrieve&db=pubmed&dopt=Abstract&list\\_uids=10458432&query\\_hl=89&itool=pubmed\\_docsum](http://www.ncbi.nlm.nih.gov/entrez/query.fcgi?cmd=Retrieve&db=pubmed&dopt=Abstract&list_uids=10458432&query_hl=89&itool=pubmed_docsum)
44. Smith CP, Somogyi GT, Chancellor MB. Emerging role of botulinum toxin in the treatment of neurogenic and non-neurogenic voiding dysfunction. *Curr Urol Rep* 2002;3:382-387.  
[http://www.ncbi.nlm.nih.gov/entrez/query.fcgi?cmd=Retrieve&db=pubmed&dopt=Abstract&list\\_uids=12354347&query\\_hl=91&itool=pubmed\\_docsum](http://www.ncbi.nlm.nih.gov/entrez/query.fcgi?cmd=Retrieve&db=pubmed&dopt=Abstract&list_uids=12354347&query_hl=91&itool=pubmed_docsum)
45. Leippold T, Reitz A, Schurch B. Botulinum toxin as a new therapy option for voiding disorders: current state of the art. *Eur Urol* 2003;44:165-174.  
[http://www.ncbi.nlm.nih.gov/entrez/query.fcgi?cmd=Retrieve&db=pubmed&dopt=Abstract&list\\_uids=12875934&query\\_hl=95&itool=pubmed\\_docsum](http://www.ncbi.nlm.nih.gov/entrez/query.fcgi?cmd=Retrieve&db=pubmed&dopt=Abstract&list_uids=12875934&query_hl=95&itool=pubmed_docsum)
46. Schulte-Baukloh H, Knispel HH, Michael T. Botulinum-A toxin in the treatment of neurogenic bladder in children. *Pediatrics*. 2002;110:420-421.  
[http://www.ncbi.nlm.nih.gov/entrez/query.fcgi?cmd=Retrieve&db=pubmed&dopt=Abstract&list\\_uids=12165609&query\\_hl=96&itool=pubmed\\_docsum](http://www.ncbi.nlm.nih.gov/entrez/query.fcgi?cmd=Retrieve&db=pubmed&dopt=Abstract&list_uids=12165609&query_hl=96&itool=pubmed_docsum)
47. Lusuardi L, Nader A, Koen M, Schrey A, Schindler M, Riccabona M. [Minimally invasive, safe treatment of the neurogenic bladder with botulinum-A-toxin in children with myelomeningocele.] *Aktuelle Urol* 2004;35:49-53. [German]  
[http://www.ncbi.nlm.nih.gov/entrez/query.fcgi?cmd=Retrieve&db=pubmed&dopt=Abstract&list\\_uids=14997415&query\\_hl=98&itool=pubmed\\_docsum](http://www.ncbi.nlm.nih.gov/entrez/query.fcgi?cmd=Retrieve&db=pubmed&dopt=Abstract&list_uids=14997415&query_hl=98&itool=pubmed_docsum)
48. Younoszai MK. Stooling problems in patients with myelomeningocele. *South Med J* 1992;85:718-724.  
[http://www.ncbi.nlm.nih.gov/entrez/query.fcgi?cmd=Retrieve&db=pubmed&dopt=Abstract&list\\_uids=1631686&query\\_hl=100&itool=pubmed\\_docsum](http://www.ncbi.nlm.nih.gov/entrez/query.fcgi?cmd=Retrieve&db=pubmed&dopt=Abstract&list_uids=1631686&query_hl=100&itool=pubmed_docsum)
49. Squire R, Kiely EM, Carr B, Ransley PG, Duffy PG. The clinical application of the Malone antegrade colonic enema. *J Pediatr Surg* 1993;28:1012-1015.  
[http://www.ncbi.nlm.nih.gov/entrez/query.fcgi?cmd=Retrieve&db=pubmed&dopt=Abstract&list\\_uids=8229586&query\\_hl=102&itool=pubmed\\_docsum](http://www.ncbi.nlm.nih.gov/entrez/query.fcgi?cmd=Retrieve&db=pubmed&dopt=Abstract&list_uids=8229586&query_hl=102&itool=pubmed_docsum)
50. Whitehead WE, Wald A, Norton NJ. Treatment options for fecal incontinence. *Dis Colon Rectum* 2001;44:131-142.  
[http://www.ncbi.nlm.nih.gov/entrez/query.fcgi?cmd=Retrieve&db=pubmed&dopt=Abstract&list\\_uids=11805574&query\\_hl=104&itool=pubmed\\_docsum](http://www.ncbi.nlm.nih.gov/entrez/query.fcgi?cmd=Retrieve&db=pubmed&dopt=Abstract&list_uids=11805574&query_hl=104&itool=pubmed_docsum)
51. Krogh K, Kvitzau B, Jorgensen TM, Laurberg S. [Treatment of anal incontinence and constipation with transanal irrigation.] *Ugeskr Laeger* 1999;161:253-256. [Danish]  
[http://www.ncbi.nlm.nih.gov/entrez/query.fcgi?cmd=Retrieve&db=pubmed&dopt=Abstract&list\\_uids=10025223&query\\_hl=106&itool=pubmed\\_docsum](http://www.ncbi.nlm.nih.gov/entrez/query.fcgi?cmd=Retrieve&db=pubmed&dopt=Abstract&list_uids=10025223&query_hl=106&itool=pubmed_docsum)
52. Van Savage JG, Yohannes P. Laparoscopic antegrade continence enema in situ appendix procedure for refractory constipation and overflow fecal incontinence in children with spina bifida. *J Urol* 2000;164:1084-1087.  
[http://www.ncbi.nlm.nih.gov/entrez/query.fcgi?cmd=Retrieve&db=pubmed&dopt=Abstract&list\\_uids=10958747&query\\_hl=109&itool=pubmed\\_docsum](http://www.ncbi.nlm.nih.gov/entrez/query.fcgi?cmd=Retrieve&db=pubmed&dopt=Abstract&list_uids=10958747&query_hl=109&itool=pubmed_docsum)
53. Aksnes G, Diseth TH, Helseth A, Edwin B, Stange M, Aafos G, Emblem R. Appendicostomy for antegrade enema: effects on somatic and psychosocial functioning in children with myelomeningocele. *Pediatrics* 2002;109:484-489.  
[http://www.ncbi.nlm.nih.gov/entrez/query.fcgi?cmd=Retrieve&db=pubmed&dopt=Abstract&list\\_uids=11875145&query\\_hl=111&itool=pubmed\\_docsum](http://www.ncbi.nlm.nih.gov/entrez/query.fcgi?cmd=Retrieve&db=pubmed&dopt=Abstract&list_uids=11875145&query_hl=111&itool=pubmed_docsum)
54. Loening-Baucke V, Desch L, Wolraich M. Biofeedback training for patients with myelomeningocele and fecal incontinence. *Dev Med Child Neurol* 1988;30:781-790.  
[http://www.ncbi.nlm.nih.gov/entrez/query.fcgi?cmd=Retrieve&db=pubmed&dopt=Abstract&list\\_uids=3234607&query\\_hl=114&itool=pubmed\\_docsum](http://www.ncbi.nlm.nih.gov/entrez/query.fcgi?cmd=Retrieve&db=pubmed&dopt=Abstract&list_uids=3234607&query_hl=114&itool=pubmed_docsum)



55. Marshall DF, Boston VE. Altered bladder and bowel function following cutaneous electrical field stimulation in children with spina bifida - interim results of a randomized double-blind placebo-controlled trial. *Eur J Pediatr Surg* 1997;7(Suppl 1):41-43.  
[http://www.ncbi.nlm.nih.gov/entrez/query.fcgi?cmd=Retrieve&db=pubmed&dopt=Abstract&list\\_uids=9497117&query\\_hl=116&itool=pubmed\\_docsum](http://www.ncbi.nlm.nih.gov/entrez/query.fcgi?cmd=Retrieve&db=pubmed&dopt=Abstract&list_uids=9497117&query_hl=116&itool=pubmed_docsum)
56. Hansson S, Caugant D, Jodal U, Svanborg-Eden C. Untreated asymptomatic bacteriuria in girls: I - Stability of urinary isolates. *BMJ* 1989;298:853-855.  
[http://www.ncbi.nlm.nih.gov/entrez/query.fcgi?cmd=Retrieve&db=pubmed&dopt=Abstract&list\\_uids=2497822&query\\_hl=118&itool=pubmed\\_docsum](http://www.ncbi.nlm.nih.gov/entrez/query.fcgi?cmd=Retrieve&db=pubmed&dopt=Abstract&list_uids=2497822&query_hl=118&itool=pubmed_docsum)
57. Hansson S, Jodal U, Lincoln K, Svanborg-Eden C. Untreated asymptomatic bacteriuria in girls: II - Effect of phenoxymethylpenicillin and erythromycin given for intercurrent infections. *BMJ* 1989;298:856-859.  
[http://www.ncbi.nlm.nih.gov/entrez/query.fcgi?cmd=Retrieve&db=pubmed&dopt=Abstract&list\\_uids=2497823&query\\_hl=120&itool=pubmed\\_docsum](http://www.ncbi.nlm.nih.gov/entrez/query.fcgi?cmd=Retrieve&db=pubmed&dopt=Abstract&list_uids=2497823&query_hl=120&itool=pubmed_docsum)
58. Hansson S, Jodal U, Noren L, Bjure J. Untreated bacteriuria in asymptomatic girls with renal scarring. *Pediatrics* 1989;84:964-968.  
[http://www.ncbi.nlm.nih.gov/entrez/query.fcgi?cmd=Retrieve&db=pubmed&dopt=Abstract&list\\_uids=2587151&query\\_hl=122&itool=pubmed\\_docsum](http://www.ncbi.nlm.nih.gov/entrez/query.fcgi?cmd=Retrieve&db=pubmed&dopt=Abstract&list_uids=2587151&query_hl=122&itool=pubmed_docsum)
59. Johnson HW, Anderson JD, Chambers GK, Arnold WJ, Irwin WJ, Brinton JR. A short-term study of nitrofurantoin prophylaxis in children managed with clean intermittent catheterization. *Pediatrics* 1994;93:752-755.  
[http://www.ncbi.nlm.nih.gov/entrez/query.fcgi?cmd=Retrieve&db=pubmed&dopt=Abstract&list\\_uids=8165073&query\\_hl=125&itool=pubmed\\_docsum](http://www.ncbi.nlm.nih.gov/entrez/query.fcgi?cmd=Retrieve&db=pubmed&dopt=Abstract&list_uids=8165073&query_hl=125&itool=pubmed_docsum)
60. Schlager TA, Anderson S, Trudell J, Hendley JO. Nitrofurantoin prophylaxis for bacteriuria and urinary tract infection in children with neurogenic bladder on intermittent catheterization. *J Pediatr* 1998;132:704-708.  
[http://www.ncbi.nlm.nih.gov/entrez/query.fcgi?cmd=Retrieve&db=pubmed&dopt=Abstract&list\\_uids=9580774&query\\_hl=127&itool=pubmed\\_docsum](http://www.ncbi.nlm.nih.gov/entrez/query.fcgi?cmd=Retrieve&db=pubmed&dopt=Abstract&list_uids=9580774&query_hl=127&itool=pubmed_docsum)
61. Nguyen DH, Mitchell ME. Gastric bladder reconstruction. *Urol Clin North Am* 1991;18:649-657.  
[http://www.ncbi.nlm.nih.gov/entrez/query.fcgi?cmd=Retrieve&db=pubmed&dopt=Abstract&list\\_uids=1949398&query\\_hl=129&itool=pubmed\\_docsum](http://www.ncbi.nlm.nih.gov/entrez/query.fcgi?cmd=Retrieve&db=pubmed&dopt=Abstract&list_uids=1949398&query_hl=129&itool=pubmed_docsum)
62. Duel BP, Gonzalez R, Barthold JS. Alternative techniques for augmentation cystoplasty. *J Urol* 1998;159:998-1005.  
[http://www.ncbi.nlm.nih.gov/entrez/query.fcgi?cmd=Retrieve&db=pubmed&dopt=Abstract&list\\_uids=9474216&query\\_hl=133&itool=pubmed\\_docsum](http://www.ncbi.nlm.nih.gov/entrez/query.fcgi?cmd=Retrieve&db=pubmed&dopt=Abstract&list_uids=9474216&query_hl=133&itool=pubmed_docsum)
63. Naglo AS. Continence training of children with neurogenic bladder and detrusor hyperactivity: effect of atropine. *Scan J Urol Nephrol* 1982;16:211-215.  
[http://www.ncbi.nlm.nih.gov/entrez/query.fcgi?cmd=Retrieve&db=pubmed&dopt=Abstract&list\\_uids=7163785&query\\_hl=135&itool=pubmed\\_docsum](http://www.ncbi.nlm.nih.gov/entrez/query.fcgi?cmd=Retrieve&db=pubmed&dopt=Abstract&list_uids=7163785&query_hl=135&itool=pubmed_docsum)
64. Austin PF, Westney OL, Leng WW, McGuire EJ, Ritchey ML. Advantages of rectus fascial slings for urinary incontinence in children with neuropathic bladders. *J Urol* 2001;165:2369-2371.  
[http://www.ncbi.nlm.nih.gov/entrez/query.fcgi?cmd=Retrieve&db=pubmed&dopt=Abstract&list\\_uids=11398778&query\\_hl=137&itool=pubmed\\_docsum](http://www.ncbi.nlm.nih.gov/entrez/query.fcgi?cmd=Retrieve&db=pubmed&dopt=Abstract&list_uids=11398778&query_hl=137&itool=pubmed_docsum)
65. Guys JM, Fakhro A, Louis-Borrione C, Prost J, Hautier A. Endoscopic treatment of urinary incontinence: long-term evaluation of the results. *J Urol* 2001;165:2389-2391.  
[http://www.ncbi.nlm.nih.gov/entrez/query.fcgi?cmd=Retrieve&db=pubmed&dopt=Abstract&list\\_uids=11371983&query\\_hl=139&itool=pubmed\\_docsum](http://www.ncbi.nlm.nih.gov/entrez/query.fcgi?cmd=Retrieve&db=pubmed&dopt=Abstract&list_uids=11371983&query_hl=139&itool=pubmed_docsum)
66. Kassouf W, Capolicchio G, Bernardinucci G, Corcos J. Collagen injection for treatment of urinary incontinence in children. *J Urol* 2001;165:1666-1668.  
[http://www.ncbi.nlm.nih.gov/entrez/query.fcgi?cmd=Retrieve&db=pubmed&dopt=Abstract&list\\_uids=11342951&query\\_hl=142&itool=pubmed\\_docsum](http://www.ncbi.nlm.nih.gov/entrez/query.fcgi?cmd=Retrieve&db=pubmed&dopt=Abstract&list_uids=11342951&query_hl=142&itool=pubmed_docsum)
67. Kryger JV, Leveson G, Gonzalez R. Long-term results of artificial urinary sphincters in children are independent of age at implantation. *J Urol* 2001;165:2377-2379.  
[http://www.ncbi.nlm.nih.gov/entrez/query.fcgi?cmd=Retrieve&db=pubmed&dopt=Abstract&list\\_uids=11371981&query\\_hl=144&itool=pubmed\\_docsum](http://www.ncbi.nlm.nih.gov/entrez/query.fcgi?cmd=Retrieve&db=pubmed&dopt=Abstract&list_uids=11371981&query_hl=144&itool=pubmed_docsum)
68. Holmes NM, Kogan BA, Baskin LS. Placement of artificial urinary sphincter in children and simultaneous gastrocystoplasty. *J Urol* 2001;165:2366-2368.  
[http://www.ncbi.nlm.nih.gov/entrez/query.fcgi?cmd=Retrieve&db=pubmed&dopt=Abstract&list\\_uids=11371944&query\\_hl=146&itool=pubmed\\_docsum](http://www.ncbi.nlm.nih.gov/entrez/query.fcgi?cmd=Retrieve&db=pubmed&dopt=Abstract&list_uids=11371944&query_hl=146&itool=pubmed_docsum)

69. Mitchell ME, Piser JA. Intestinocystoplasty and total bladder replacement in children and young adults: follow up in 129 cases. *J Urol* 1987;138:579-584.  
[http://www.ncbi.nlm.nih.gov/entrez/query.fcgi?cmd=Retrieve&db=pubmed&dopt=Abstract&list\\_uids=3625861&query\\_hl=148&itool=pubmed\\_docsum](http://www.ncbi.nlm.nih.gov/entrez/query.fcgi?cmd=Retrieve&db=pubmed&dopt=Abstract&list_uids=3625861&query_hl=148&itool=pubmed_docsum)
70. Shekarriz B, Upadhyay J, Demirbilek S, Barthold JS, Gonzalez R. Surgical complications of bladder augmentation: comparison between various enterocystoplasties in 133 patients. *Urology* 2000;55:123-128.  
[http://www.ncbi.nlm.nih.gov/entrez/query.fcgi?cmd=Retrieve&db=pubmed&dopt=Abstract&list\\_uids=10654908&query\\_hl=150&itool=pubmed\\_docsum](http://www.ncbi.nlm.nih.gov/entrez/query.fcgi?cmd=Retrieve&db=pubmed&dopt=Abstract&list_uids=10654908&query_hl=150&itool=pubmed_docsum)
71. Medel R, Ruarte AC, Herrera M, Castera R, Podesta ML. Urinary continence outcome after augmentation ileocystoplasty as a single surgical procedure in patients with myelodysplasia. *J Urol* 2002;168:1849-1852.  
[http://www.ncbi.nlm.nih.gov/entrez/query.fcgi?cmd=Retrieve&db=pubmed&dopt=Abstract&list\\_uids=12352374&query\\_hl=152&itool=pubmed\\_docsum](http://www.ncbi.nlm.nih.gov/entrez/query.fcgi?cmd=Retrieve&db=pubmed&dopt=Abstract&list_uids=12352374&query_hl=152&itool=pubmed_docsum)

## 12. DILATATION OF THE UPPER URINARY TRACT (URETEROPELVIC JUNCTION AND URETEROVESICAL JUNCTION OBSTRUCTION)

### 12.1 Background

Dilatation of the upper urinary tract still presents a significant clinical challenge in determining which patient may gain benefit from therapy.

Ureteropelvic junction (UPJ) obstruction is defined as impaired urine flow from the pelvis into the proximal ureter with subsequent dilatation of the collecting system and the potential to damage the kidney. It is the most common cause of neonatal hydronephrosis (1). It has an overall incidence of 1:1500 and a ratio of males to females of 2:1 in newborns.

Ureterovesical junction (UVJ) obstruction is an obstructive condition of the distal ureter as it enters the bladder, commonly called a primary obstructive megaureter. Megaureters are ranked as second in the differential diagnosis of neonatal hydronephrosis. They occur more often in males and are more likely to occur on the left side (2).

Much more difficult is the definition of obstruction, which is still unclear. Creating a divide between 'obstructed' and 'non-obstructed' urinary tracts, as if entities could be as clearly differentiated as 'black' and 'white', is impossible. Currently, the most popular definition is that obstruction represents any restriction to urinary outflow that, if left untreated, will cause progressive renal deterioration (3).

### 12.2 Diagnosis

Due to the widespread use of ultrasonography during pregnancy, antenatal hydronephrosis is being detected with increasing frequency (4). The challenge in the management of dilated upper urinary tracts is to decide which child can be observed, which one can be managed medically, and which one requires surgical intervention. There is no single test alone among the diagnostic armamentarium that is definitive for distinguishing obstructive from non-obstructive cases (Figure 2).

#### 12.2.1 Antenatal ultrasound

Usually between the 16th and 18th weeks of pregnancy, the kidneys are visualized routinely, when almost all amniotic fluid consists of urine. The most sensitive time for fetal urinary tract evaluation is the 28th week. If dilatation is detected, ultrasound should focus on the laterality, severity of dilatation, and echogenicity of the kidneys, hydronephrosis or hydro-ureteronephrosis, bladder volume and bladder emptying, sex of the child, and amniotic fluid volume, respectively (5).

#### 12.2.2 Postnatal ultrasound

Since transitory neonatal dehydration lasts about 48 hours, imaging should be performed after this period of postnatal oliguria. In severe cases (bilateral dilatation, solitary kidney, oligohydramnios), immediate postnatal sonography is recommended (6). During ultrasound examination, the anteroposterior diameter of the renal pelvis, calyceal dilatation, kidney size, thickness of the parenchyma, cortical echogenicity, ureters, bladder wall and residual urine are assessed.

### 12.2.3 Voiding cystourethrogram (VCUG)

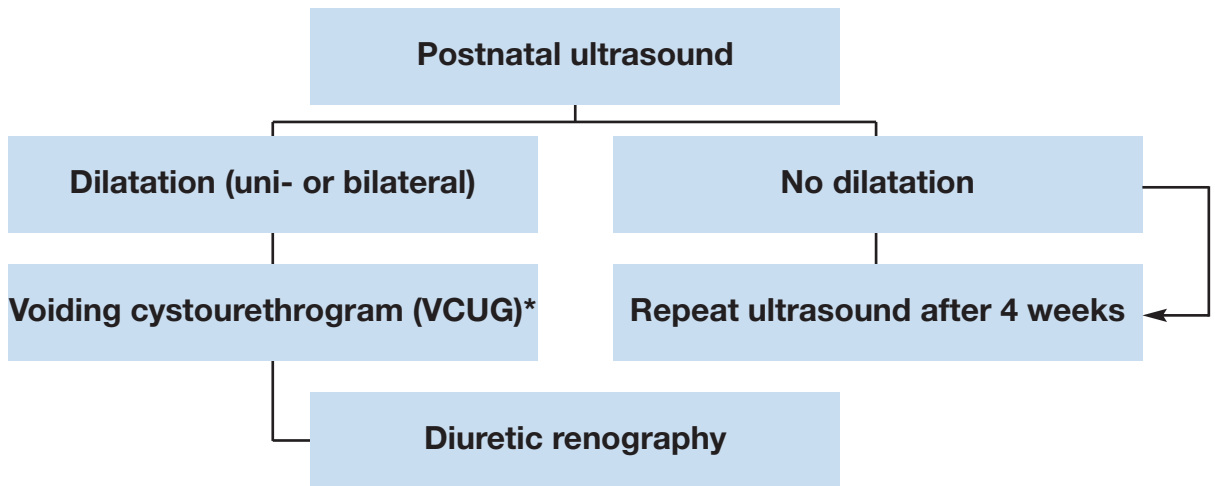
In newborns with identified upper urinary tract dilatation, the presence of primary or important associated factors that must be detected include VUR in up to 25% of affected children (15), urethral valves, ureteroceles, diverticula and neurogenic bladder. Conventional VCUG is the method of choice for primary diagnostic procedures (7).

### 12.2.4 Diuretic renography

Diuretic renography is the most commonly used diagnostic tool to detect the severity and functional significance of urine transport problems. <sup>99m</sup>Tc-MAG3 is the radionuclide of choice. It is important to perform the study under standardized circumstances (hydration, transurethral catheter) between the fourth and sixth weeks of life (8).

Oral fluid intake is encouraged prior to the examination and, 15 minutes before the injection of the radionuclide, normal saline intravenous infusion at a rate of 15 mL/kg over 30 minutes is mandatory, with a subsequent maintenance rate of 4 mL/kg/hr throughout the whole time of the investigation (9). The recommended dose of furosemide is 1 mg/kg for infants during the first year of life, while 0.5 mg/kg should be given to children aged 1 to 16 years up to a maximum dose of 40 mg.

**Figure 2. Diagnostic algorithm for dilatation of the upper urinary tract**



\* A diagnostic work-up including VCUG has to be discussed with the parents since a possibly detected reflux might have absolutely no clinical impact. On the other hand a reflux rate of up to 25% in cases of prenatally detected and postnatally confirmed hydronephrosis is reported in the literature (15) and might therefore have some forensic impact as well.

## 12.3 Treatment

### 12.3.1 Prenatal management

Counselling the parents is one of the most important aspects of care. The prognosis for an hydronephrotic kidney, even if severely affected, is hopeful. An hydronephrotic kidney may still be capable of delivering meaningful renal function, whereas a severely hypoplastic and dysplastic kidney has a hopeless outlook. It is important to explain to the parents the timing and accuracy of establishing the definitive diagnosis for their child. In some cases, there is an obvious indication of severity, including massive bilateral dilatation, bilateral evidence of hypoplastic dysplasia, progressive bilateral dilatation with oligohydramnios, and pulmonary hypoplasia.

Intrauterine intervention is rarely indicated and should only be performed in well-experienced centres (10).

### 12.3.2 UPJ obstruction

It is most important to make the decision on the basis of serial investigations applying the same technique and performed by the same institution under standardized circumstances. Symptomatic obstruction (recurrent flank pain, urinary tract infection) requires surgical correction using a pyeloplasty, according to the standardized open technique of Hynes and Anderson (11). In asymptomatic cases, conservative follow-up can be the treatment of choice.

Indications for surgical intervention comprise impaired split renal function (less than 40%), a decrease in split renal function of more than 10% in subsequent studies, increased anteroposterior diameter on the

ultrasound, and grade III and IV dilatation as defined by the Society for Fetal Urology.

### 12.3.3 Megaureter

Concerning the treatment options of secondary megaureters, see (reflux & valves, Section 13.4.2 ). [Note: These details to be confirmed.] If a functional study reveals and confirms adequate ureteral drainage, conservative management is the best option. Initially, low-dose prophylactic antibiotics within the first year of life are recommended for the prevention of urinary tract infections, although there are no existing prospective randomized trials evaluating the benefit of this regimen (12).

With spontaneous remission rates of up to 85% in primary megaureter cases, surgical management is no longer recommended except for megaureters with recurrent urinary tract infections, deterioration in split renal function and significant obstruction (13).

The initial approach to the ureter can be either intravesical, extravesical, or combined. Straightening the ureter is necessary without devascularization. Ureteral tapering should enhance urinary flow into the bladder. The ureter must be tapered to achieve a diameter for an antireflux repair. Several tailoring techniques exist, such as ureteral imbrication or excisional tapering (14).

## 12.4 Conclusion

With the use of routine perinatal sonography, hydronephrosis caused by UPJ or UVJ obstruction is now recognized in increasing numbers. Meticulous and repeat postnatal evaluation is mandatory to try to identify those obstructive cases at risk of renal deterioration and requiring surgical reconstruction. Surgical methods are quite standardized and have a good clinical outcome.

## 12.5 REFERENCES

1. Lebowitz RL, Griscom NT. Neonatal hydronephrosis: 146 cases. *Radiol Clin North Am* 1977;15:49-59. [http://www.ncbi.nlm.nih.gov/entrez/query.fcgi?cmd=Retrieve&db=pubmed&dopt=Abstract&list\\_uids=139634&query\\_hl=44&itool=pubmed\\_DocSum](http://www.ncbi.nlm.nih.gov/entrez/query.fcgi?cmd=Retrieve&db=pubmed&dopt=Abstract&list_uids=139634&query_hl=44&itool=pubmed_DocSum)
2. Brown T, Mandell J, Lebowitz RL. Neonatal hydronephrosis in the era of sonography. *Am J Roentgenol* 1987;148:959-963. [http://www.ncbi.nlm.nih.gov/entrez/query.fcgi?cmd=Retrieve&db=pubmed&dopt=Abstract&list\\_uids=3034009&query\\_hl=43&itool=pubmed\\_DocSum](http://www.ncbi.nlm.nih.gov/entrez/query.fcgi?cmd=Retrieve&db=pubmed&dopt=Abstract&list_uids=3034009&query_hl=43&itool=pubmed_DocSum)
3. Koff SA. Problematic ureteropelvic junction obstruction. *J Urol* 1987;138:390. [http://www.ncbi.nlm.nih.gov/entrez/query.fcgi?cmd=Retrieve&db=pubmed&dopt=Abstract&list\\_uids=3599261&query\\_hl=48&itool=pubmed\\_docsum](http://www.ncbi.nlm.nih.gov/entrez/query.fcgi?cmd=Retrieve&db=pubmed&dopt=Abstract&list_uids=3599261&query_hl=48&itool=pubmed_docsum)
4. Gunn TR, Mora JD, Pease P. Antenatal diagnosis of urinary tract abnormalities by ultrasonography after 28 weeks' gestation: incidence and outcome. *Am J Obstet Gynecol* 1995;172:479-486. [http://www.ncbi.nlm.nih.gov/entrez/query.fcgi?cmd=Retrieve&db=pubmed&dopt=Abstract&list\\_uids=7856673&query\\_hl=52&itool=pubmed\\_docsum](http://www.ncbi.nlm.nih.gov/entrez/query.fcgi?cmd=Retrieve&db=pubmed&dopt=Abstract&list_uids=7856673&query_hl=52&itool=pubmed_docsum)
5. Grignon A, Filiatrault D, Homsy Y, Robitaille P, Filion R, Boutin H, Leblond R. Ureteropelvic junction stenosis: antenatal ultrasonographic diagnosis, postnatal investigation, and follow-up. *Radiology* 1986;160:649-651. [http://www.ncbi.nlm.nih.gov/entrez/query.fcgi?cmd=Retrieve&db=pubmed&dopt=Abstract&list\\_uids=3526403&query\\_hl=27&itool=pubmed\\_docsum](http://www.ncbi.nlm.nih.gov/entrez/query.fcgi?cmd=Retrieve&db=pubmed&dopt=Abstract&list_uids=3526403&query_hl=27&itool=pubmed_docsum)
6. Flashner SC, King LR. Ureteropelvic junction. In: *Clinical pediatric urology*. Philadelphia: WB Saunders, 1976, p. 693.
7. Ebel KD. Uroradiology in the fetus and newborn: diagnosis and follow-up of congenital obstruction of the urinary tract. *Pediatr Radiol* 1998;28:630-635. [http://www.ncbi.nlm.nih.gov/entrez/query.fcgi?cmd=Retrieve&db=pubmed&dopt=Abstract&list\\_uids=9716640&query\\_hl=59&itool=pubmed\\_docsum](http://www.ncbi.nlm.nih.gov/entrez/query.fcgi?cmd=Retrieve&db=pubmed&dopt=Abstract&list_uids=9716640&query_hl=59&itool=pubmed_docsum)
8. O'Reilly P, Aurell M, Britton K, Kletter K, Rosenthal L, Testa T. Consensus on diuresis renography for investigating the dilated upper urinary tract. Radionuclides in Nephrourology Group. Consensus Committee on Diuresis Renography. *J Nucl Med* 1996;37:1872-1876. [http://www.ncbi.nlm.nih.gov/entrez/query.fcgi?cmd=Retrieve&db=pubmed&dopt=Abstract&list\\_uids=8917195&query\\_hl=62&itool=pubmed\\_docsum](http://www.ncbi.nlm.nih.gov/entrez/query.fcgi?cmd=Retrieve&db=pubmed&dopt=Abstract&list_uids=8917195&query_hl=62&itool=pubmed_docsum)
9. Choong KK, Gruenewald SM, Hodson EM, Antico VF, Farlow DC, Cohen RC. Volume expanded diuretic renography in the postnatal assessment of suspected uretero-pelvic junction obstruction. *J Nucl Med* 1992;33:2094-2098. [http://www.ncbi.nlm.nih.gov/entrez/query.fcgi?cmd=Retrieve&db=pubmed&dopt=Abstract&list\\_uids=1460498&query\\_hl=64&itool=pubmed\\_docsum](http://www.ncbi.nlm.nih.gov/entrez/query.fcgi?cmd=Retrieve&db=pubmed&dopt=Abstract&list_uids=1460498&query_hl=64&itool=pubmed_docsum)

10. Reddy PP, Mandell J. Prenatal diagnosis. Therapeutic implications. *Urol Clin North Am* 1998; 25:171-180.  
[http://www.ncbi.nlm.nih.gov/entrez/query.fcgi?cmd=Retrieve&db=pubmed&dopt=Abstract&list\\_uids=9633572&query\\_hl=66&itool=pubmed\\_docsum](http://www.ncbi.nlm.nih.gov/entrez/query.fcgi?cmd=Retrieve&db=pubmed&dopt=Abstract&list_uids=9633572&query_hl=66&itool=pubmed_docsum)
11. Novick AC, Stroom AB. Surgery of the kidney. In: *Campbell's urology*. Philadelphia, WB Saunders: 1998, p. 3044.
12. Arena F, Baldari S, Proietto F, Centorrino A, Scalfari G, Romeo G. Conservative treatment in primary neonatal megaureter. *Eur J Pediatr Surg* 1998;8:347-351.  
[http://www.ncbi.nlm.nih.gov/entrez/query.fcgi?cmd=Retrieve&db=pubmed&dopt=Abstract&list\\_uids=9926303&query\\_hl=71&itool=pubmed\\_docsum](http://www.ncbi.nlm.nih.gov/entrez/query.fcgi?cmd=Retrieve&db=pubmed&dopt=Abstract&list_uids=9926303&query_hl=71&itool=pubmed_docsum)
13. Peters CA, Mandell J, Lebowitz RL, Colodny AH, Bauer SB, Hendren WH, Retik AB. Congenital obstructed megaureters in early infancy: diagnosis and treatment. *J Urol* 1989;142:641-645.  
[http://www.ncbi.nlm.nih.gov/entrez/query.fcgi?cmd=Retrieve&db=pubmed&dopt=Abstract&list\\_uids=2746792&query\\_hl=72&itool=pubmed\\_docsum](http://www.ncbi.nlm.nih.gov/entrez/query.fcgi?cmd=Retrieve&db=pubmed&dopt=Abstract&list_uids=2746792&query_hl=72&itool=pubmed_docsum)
14. Sripathi V, King PA, Thomson MR, Bogle MS. Primary obstructive megaureter. *J Pediatr Surg* 1991;26:826-829.  
[http://www.ncbi.nlm.nih.gov/entrez/query.fcgi?cmd=Retrieve&db=pubmed&dopt=Abstract&list\\_uids=1895193&query\\_hl=74&itool=pubmed\\_docsum](http://www.ncbi.nlm.nih.gov/entrez/query.fcgi?cmd=Retrieve&db=pubmed&dopt=Abstract&list_uids=1895193&query_hl=74&itool=pubmed_docsum)
15. Thomas DF. Prenatally detected uropathy: epidemiological considerations. *Br J Urol* 1998 Apr;81 (Suppl 2):8-12.

## 13. VESICoureTERIC REFLUX (VUR)

### 13.1 Background

Vesicoureteric reflux (VUR) is a very common urological anomaly in children and is probably one of the most controversial issues in paediatrics (1). Vesicoureteric reflux is defined as the non-physiological back-flow of urine from the urinary bladder into the ureter or the renal pelvis and the calyces. While primary VUR is a congenital anomaly of the ureterovesical junction with a genetic basis (2), secondary reflux is caused by an anatomical or functional bladder outflow obstruction and subsequently elevated pressures or inflammatory diseases. Primary VUR can be associated with other morphological and/or functional abnormalities of the lower urinary tract.

About 1-2% of all children have VUR, while VUR occurs in 25-40% of children with acute pyelonephritis (1). In newborns, the incidence of reflux is higher in boys than in girls, but in later life, girls are approximately 4-6 times more frequently affected than boys. The incidence of prenatally diagnosed hydronephrosis caused by VUR ranges from 17-37% (3,4). About 30-50% of children with symptomatic VUR have radiological evidence of renal scarring, resulting from congenital dysplasia and/or acquired post-infectious damage. Intrarenal reflux of infected urine appears to be primarily responsible for the renal damage.

Reflux nephropathy (RN) may be the most common cause of childhood hypertension. Follow-up studies show that about 10-20% of children with RN develop hypertension or end-stage renal disease (5). Older studies have consistently attributed 15-30% of chronic renal failure in children and young adults to chronic pyelonephritis and RN (6). However, an awareness of VUR-related morbidity has led to more widespread diagnosis and treatment, which appears to have resulted in a decrease in the number of affected patients with RN. The diagnosis and treatment of VUR has therefore altered the epidemiology of hypertension and renal failure in children and young adults. In a recent series of renal transplant populations, approximately 2-3% of cases were related to chronic pyelonephritis (7).

Twin and family studies have revealed that VUR has a genetic basis (2). Siblings of patients with known reflux have an approximately 30% prevalence of reflux, with younger siblings being at greatest risk. Offspring of parents with reflux have an almost 70% risk of developing reflux. Since siblings and offspring of sufferers are mostly asymptomatic, it is advised that they should be routinely screened for reflux (8,9).

The management of affected children has been directed at preventing infection and permanent renal parenchymal damage and its late complications by antibiotic prophylaxis and/or surgical correction of reflux. However, controversy remains regarding the optimal strategies for management of children with primary VUR (10-12).

### 13.2 Classification

In 1985, the International Reflux Study Committee introduced a uniform system for the classification of VUR (13) (Table 1). The grading system combines two earlier classifications and is based upon the extent of

retrograde filling and dilatation of the ureter, the renal pelvis and the calyces on a VCUG. The Committee also described a standardized technique of VCUG to allow comparability of results.

**Table 1: Grading system for vesicoureteric reflux, according to the International Reflux Study Committee (13)**

Grade I	Reflux does not reach the renal pelvis; varying degrees of ureteral dilatation
Grade II	Reflux reaches the renal pelvis; no dilatation of the collecting system; normal fornices
Grade III	Mild or moderate dilatation of the ureter, with or without kinking; moderate dilatation of the collecting system; normal or minimally deformed fornices
Grade IV	Moderate dilatation of the ureter with or without kinking; moderate dilatation of the collecting system; blunt fornices, but impressions of the papillae still visible
Grade V	Gross dilatation and kinking of the ureter, marked dilatation of the collecting system; papillary impressions no longer visible; intraparenchymal reflux

### 13.3 Diagnostic work-up

A basic diagnostic work-up comprises a detailed medical history (including family history), physical examination, urinalysis, urine culture and, if renal function needs to be assessed, serum creatinine level. Diagnostic imaging for VUR encompasses both radiological and sonographic modalities (14). Radiological modalities comprise VCUG, the most widespread method for examination of reflux, and radionuclide cystography (RNC).

In RNC, radiation exposure is significantly lower than in VCUG with continuous fluoroscopy, but the anatomical details depicted are much more inferior. With the introduction of pulsed fluoroscopy, the radiation exposure of VCUG could be markedly reduced. The use of VCUG allows the grade of reflux to be determined (in a single or duplicated kidney) and the assessment of bladder and ureteral configuration. Moreover, VCUG is the study of choice for imaging the urethra. The sonographic diagnosis of VUR with intravesical administration of an ultrasound (US) contrast agent (voiding urosonography [VUS]) is mostly used as the primary reflux examination modality in girls and during follow-up.

In complex cases, magnetic resonance urography may be required for evaluation of the upper urinary tract.

Dimercaptosuccinic acid (DMSA) is the best nuclear agent for visualizing cortical tissue, evaluating renal parenchyma, and documenting the presence of renal scars. Children with normal DMSA during an acute UTI have a low risk of renal damage. Children with normal follow-up DMSA and low-grade VUR have more frequent spontaneous resolution of VUR (15).

In the case of incontinence or residual urine, urodynamic studies can be performed to reveal functional abnormalities of the lower urinary tract. Such testing is most important in patients in whom secondary reflux is suspected, such as patients with spina bifida or boys whose VCUG is suggestive of residual posterior urethral valves. Yet, in most cases of non-neurogenic voiding dysfunction, diagnosis and follow-up can be limited to non-invasive tests (voiding charts, US, uroflowmetry). In the few remaining children with inconclusive findings and who are refractory to treatment, urodynamic tests are necessary. Appropriate management of voiding dysfunction will often result in the resolution of reflux (16).

In the past, cystoscopy was considered to be essential for the assessment of VUR. The position and shape of the ureteral orifices were thought to correlate with the grade and prognosis. Subsequent data have demonstrated that cystoscopic observations do not contribute significantly to the outcome of management (17). Cystoscopy may be performed at the time of open surgery to identify additional anatomical abnormalities, such as ureteral duplication and ureteral ectopia.

### 13.4 Treatment

Early diagnosis and vigilant monitoring are the cornerstones of treatment (Table 2). The ultimate objective of treatment is to allow normal renal growth and to prevent permanent renal parenchymal damage and its late complications (reflux nephropathy, see above). There is no single therapeutic strategy for all clinical settings of VUR.

Therapeutic options comprise conservative (medical) management, including antibiotic prophylaxis, and interventional approaches (i.e. endoscopic subureteral injection, laparoscopic or open surgical correction of reflux), in isolation or combined.

The individual choice of management is based on the presence of renal scars, the clinical course, grade of reflux, ipsilateral renal function, bilaterality, bladder capacity and function, associated anomalies of the urinary tract, age, compliance and parental preference.

Surgical correction is warranted in recurrent febrile infections despite antibiotic prophylaxis

(breakthrough infections), medical non-compliance, and new scars and in the presence of associated malformations (e.g. duplex systems, Hutch diverticulum, ectopic ureter).

In secondary VUR, the objective of management is treatment of the underlying condition. If VUR persists after successful therapy of the underlying condition, further management depends on the individual clinical setting.

**Table 2: Treatment of reflux**

Patient's age	Grade of reflux/Gender	Management
< 1 year		Conservative
1-5 year (s)	Grade I-III	Conservative
	Grade IV-V	Surgical correction
> 5 years	Boys	Indication for surgery is rare
	Girls	Surgical correction

#### 13.4.1 Conservative approach

The rationale for conservative management is the observation that VUR can resolve spontaneously with time, mostly in young patients with low-grade reflux (81% and 48% in VUR grades I-II and III-V, respectively) (18,19). The objective of conservative therapy is prevention of febrile UTI.

Education and consistent follow-up of the patient and parent, high fluid intake, regular and complete emptying of the bladder (if necessary with double micturition) and low-dose antibiotic prophylaxis are key aspects of conservative management. In boys with low-grade VUR, circumcision may be advised.

Conservative management should be dismissed in favour of surgical intervention in all cases of febrile breakthrough infections, as well as in girls in whom VUR has persisted up to an age at which spontaneous resolution can no longer be expected. In boys 5 years and older antibiotic prophylaxis may be stopped, and indications for surgical reflux correction are rare.

#### 13.4.2 Interventional therapy

##### 13.4.2.1 Open surgery

Various intra- and extra-vesical techniques have been described for the surgical correction of reflux. Although different methods have specific advantages and complications, they all share the basic principle of lengthening the intramural part of the ureter by submucosal embedding of the ureter. All techniques have been shown to be safe with a low rate of complications and excellent success rates (92-98%). Currently, the most popular procedures are the Lich-Gregoir, Politano-Leadbetter, Cohen and Psoas-Hitch ureteroneocystostomy (20,21).

Surgery in early infancy carries a high risk of severely damaging bladder function. If an extravesical procedure is planned, cystoscopy should be performed preoperatively to assess the bladder mucosa and position and configuration of the ureteric orifices. In bilateral reflux, intravesical antireflux procedures may be considered, as simultaneous bilateral extravesical reflux repair carries an increased risk of temporary post-operative urine retention (22).

##### 13.4.2.2 Laparoscopic reflux correction

In a small number of children, VUR has been corrected laparoscopically. Although success rates are similar to open surgery, laparoscopic reflux correction takes significantly longer and therefore has no obvious advantages (23). At present, a laparoscopic approach cannot be recommended as a routine procedure (24).

##### 13.4.2.3 Endoscopic therapy

Although still mainly experimental, endoscopic treatment of VUR offers the advantage of enabling treatment of the underlying anatomical defect while avoiding the morbidity of open surgery (25). With the availability of biodegradable substances, endoscopic subureteral injection of tissue-augmenting substances (bulking agents) have become an alternative to long-term antibiotic prophylaxis and surgical intervention in the treatment of VUR in children (26). Although there is not yet a prospective trial proving that endoscopic therapy is equally effective as the conservative management, endoscopic therapy is currently being used as the initial treatment of reflux in some centres. A sound clinical validation of its effectiveness is currently hampered by the lack of methodologically appropriate studies. In a recent meta-analysis (27), including 5,527 patients and 8,101 renal units, the reflux resolution rate (by ureter) following one treatment for grades I and II reflux was 78.5%, grade III 72%, grade IV 63% and grade V 51%. If the first injection was unsuccessful, the second treatment had a success rate of 68%, and the third treatment 34%. The aggregate success rate with one or more injections was 85%. The success rate was significantly lower for duplicated (50%) versus single systems (73%), and

neuropathic (62%) versus normal bladders (74%).

### 13.5 Follow-up

Follow-up after surgical correction of VUR is a controversial issue. In a recent update of the International Reflux Study, the authors published the results of urography at 10 years after either medical or surgical treatment of VUR. They concluded that with careful management, only a small proportion of children with severe reflux developed new scars and then rarely after the first 5-year follow-up period, and that there was no difference between children treated medically or surgically (28). Routine radionuclide studies are therefore not recommended.

As post-operative VCUG does not allow identification of children at risk of developing febrile UTI, this investigation is optional. Although VCUG may not be necessary in clinically asymptomatic cases after open surgery (29), it is mandatory following endoscopic treatment.

Obstruction of the upper urinary tract is ruled out by sonography at discharge and 3 months post-operatively. The follow-up protocol should include blood pressure measurement and urinalysis.

### 13.6 REFERENCES

1. Fanos V, Cataldi L. Antibiotics or surgery for vesicoureteric reflux in children. *Lancet* 2004;364:1720-1722.  
[http://www.ncbi.nlm.nih.gov/entrez/query.fcgi?cmd=Retrieve&db=pubmed&dopt=Abstract&list\\_uids=15530633&query\\_hl=1&itool=pubmed\\_docsum](http://www.ncbi.nlm.nih.gov/entrez/query.fcgi?cmd=Retrieve&db=pubmed&dopt=Abstract&list_uids=15530633&query_hl=1&itool=pubmed_docsum)
2. Murawski IJ, Gupta IR. Vesicoureteric reflux and renal malformations: a developmental problem. *Clin Genet* 2006;69:105-117.  
[http://www.ncbi.nlm.nih.gov/entrez/query.fcgi?cmd=Retrieve&db=pubmed&dopt=Abstract&list\\_uids=16433689&query\\_hl=3&itool=pubmed\\_docsum](http://www.ncbi.nlm.nih.gov/entrez/query.fcgi?cmd=Retrieve&db=pubmed&dopt=Abstract&list_uids=16433689&query_hl=3&itool=pubmed_docsum)
3. Anderson NG, Wright S, Abbott GD, Wells JE, Mogridge N. Fetal renal pelvic dilatation - poor predictor of familial vesicoureteric reflux. *Pediatr Nephrol* 2003;18:902-905.  
[http://www.ncbi.nlm.nih.gov/entrez/query.fcgi?cmd=Retrieve&db=pubmed&dopt=Abstract&list\\_uids=12883970&query\\_hl=5&itool=pubmed\\_docsum](http://www.ncbi.nlm.nih.gov/entrez/query.fcgi?cmd=Retrieve&db=pubmed&dopt=Abstract&list_uids=12883970&query_hl=5&itool=pubmed_docsum)
4. Phan V, Traubici J, Hershenfield B, Stephens D, Rosenblum ND, Geary DF. Vesicoureteral reflux in infants with isolated antenatal hydronephrosis. *Pediatr Nephrol* 2003;18:1224-1228.  
[http://www.ncbi.nlm.nih.gov/entrez/query.fcgi?cmd=Retrieve&db=pubmed&dopt=Abstract&list\\_uids=14586679&query\\_hl=7&itool=pubmed\\_docsum](http://www.ncbi.nlm.nih.gov/entrez/query.fcgi?cmd=Retrieve&db=pubmed&dopt=Abstract&list_uids=14586679&query_hl=7&itool=pubmed_docsum)
5. Blumenthal I. Vesicoureteric reflux and urinary tract infection in children. *Postgrad Med J* 2006;82:31-35.  
[http://www.ncbi.nlm.nih.gov/entrez/query.fcgi?cmd=Retrieve&db=pubmed&dopt=Abstract&list\\_uids=16397077&query\\_hl=9&itool=pubmed\\_docsum](http://www.ncbi.nlm.nih.gov/entrez/query.fcgi?cmd=Retrieve&db=pubmed&dopt=Abstract&list_uids=16397077&query_hl=9&itool=pubmed_docsum)
6. Ardissino G, Avolio L, Dacco V, Testa S, Marra G, Vigano S, Loi S, Caione P, De Castro R, De Pascale S, Marras E, Riccipetroni G, Selvaggio G, Pedotti P, Claris-Appiani A, Ciofani A, Dello Strologo L, Lama G, Montini G, Verrina E; Italkid Project. Long-term outcome of vesicoureteral reflux associated chronic renal failure in children. Data from the Italkid Project. *J Urol* 2004;172:305-310.  
[http://www.ncbi.nlm.nih.gov/entrez/query.fcgi?cmd=Retrieve&db=pubmed&dopt=Abstract&list\\_uids=15201801&query\\_hl=11&itool=pubmed\\_docsum](http://www.ncbi.nlm.nih.gov/entrez/query.fcgi?cmd=Retrieve&db=pubmed&dopt=Abstract&list_uids=15201801&query_hl=11&itool=pubmed_docsum)
7. Vallee JP, Vallee MP, Greenfield SP, Wan J, Springate J. Contemporary incidence of morbidity related to vesicoureteral reflux. *Urology* 1999;53:812-815.  
[http://www.ncbi.nlm.nih.gov/entrez/query.fcgi?cmd=Retrieve&db=pubmed&dopt=Abstract&list\\_uids=10197863&query\\_hl=13&itool=pubmed\\_docsum](http://www.ncbi.nlm.nih.gov/entrez/query.fcgi?cmd=Retrieve&db=pubmed&dopt=Abstract&list_uids=10197863&query_hl=13&itool=pubmed_docsum)
8. Hollowell JG, Greenfield SP. Screening siblings for vesicoureteral reflux. *J Urol* 2002;168:2138-2141.  
[http://www.ncbi.nlm.nih.gov/entrez/query.fcgi?cmd=Retrieve&db=pubmed&dopt=Abstract&list\\_uids=12394743&query\\_hl=16&itool=pubmed\\_docsum](http://www.ncbi.nlm.nih.gov/entrez/query.fcgi?cmd=Retrieve&db=pubmed&dopt=Abstract&list_uids=12394743&query_hl=16&itool=pubmed_docsum)
9. Giel DW, Noe HN, Williams MA. Ultrasound screening of asymptomatic siblings of children with vesicoureteral reflux: a long-term followup study. *J Urol* 2005;174:1602-1604.  
[http://www.ncbi.nlm.nih.gov/entrez/query.fcgi?cmd=Retrieve&db=pubmed&dopt=Abstract&list\\_uids=16148662&query\\_hl=18&itool=pubmed\\_docsum](http://www.ncbi.nlm.nih.gov/entrez/query.fcgi?cmd=Retrieve&db=pubmed&dopt=Abstract&list_uids=16148662&query_hl=18&itool=pubmed_docsum)
10. Elder JS, Peters CA, Arant BS Jr, Ewalt DH, Hawtrey CE, Hurwitz RS, Parrott TS, Snyder HM 3rd, Weiss RA, Woolf SH, Hasselblad V. Pediatric Vesicoureteral Reflux Guidelines Panel summary report on the management of primary vesicoureteral reflux in children. *J Urol* 1997;157:1846-1851.  
[http://www.ncbi.nlm.nih.gov/entrez/query.fcgi?cmd=Retrieve&db=pubmed&dopt=Abstract&list\\_uids=9112544&query\\_hl=20&itool=pubmed\\_docsum](http://www.ncbi.nlm.nih.gov/entrez/query.fcgi?cmd=Retrieve&db=pubmed&dopt=Abstract&list_uids=9112544&query_hl=20&itool=pubmed_docsum)



11. Smellie JM, Barratt TM, Chantler C, Gordon I, Prescod NP, Ransley PG, Woolf AS. Medical versus surgical treatment in children with severe bilateral vesicoureteric reflux and bilateral nephropathy: a randomised trial. *Lancet* 2001;357:1329-1333.  
[http://www.ncbi.nlm.nih.gov/entrez/query.fcgi?cmd=Retrieve&db=pubmed&dopt=Abstract&list\\_uids=11343739&query\\_hl=4&itool=pubmed\\_docsum](http://www.ncbi.nlm.nih.gov/entrez/query.fcgi?cmd=Retrieve&db=pubmed&dopt=Abstract&list_uids=11343739&query_hl=4&itool=pubmed_docsum)
12. Wheeler DM, Vimalachandra D, Hodson EM, Roy LP, Smith GH, Craig JC. Interventions for primary vesicoureteric reflux. *Cochrane Database Syst Rev* 2004; (3):CD001532.  
[http://www.ncbi.nlm.nih.gov/entrez/query.fcgi?cmd=Retrieve&db=pubmed&dopt=Abstract&list\\_uids=15266449&query\\_hl=23&itool=pubmed\\_docsum](http://www.ncbi.nlm.nih.gov/entrez/query.fcgi?cmd=Retrieve&db=pubmed&dopt=Abstract&list_uids=15266449&query_hl=23&itool=pubmed_docsum)
13. Lebowitz RL, Olbing H, Parkkulainen KV, Smellie JM, Tamminen-Mobius TE. International Reflux Study in Children: international system of radiographic grading of vesicoureteric reflux. *Pediatr Radiol* 1985;15:105-109.
14. Darge K, Riedmiller H. Current status of vesicoureteral reflux diagnosis. *World J Urol* 2004;22:88-95.  
[http://www.ncbi.nlm.nih.gov/entrez/query.fcgi?cmd=Retrieve&db=pubmed&dopt=Abstract&list\\_uids=15173954&query\\_hl=31&itool=pubmed\\_docsum](http://www.ncbi.nlm.nih.gov/entrez/query.fcgi?cmd=Retrieve&db=pubmed&dopt=Abstract&list_uids=15173954&query_hl=31&itool=pubmed_docsum)
15. Camacho V, Estorch M, Fraga G, Mena E, Fuentes J, Hernandez MA, Flotats A, Carrio I. DMSA study performed during febrile urinary tract infection: a predictor of patient outcome? *Eur J Nucl Med Mol Imaging* 2004;31:862-866.  
[http://www.ncbi.nlm.nih.gov/entrez/query.fcgi?cmd=Retrieve&db=pubmed&dopt=Abstract&list\\_uids=14758509&query\\_hl=33&itool=pubmed\\_docsum](http://www.ncbi.nlm.nih.gov/entrez/query.fcgi?cmd=Retrieve&db=pubmed&dopt=Abstract&list_uids=14758509&query_hl=33&itool=pubmed_docsum)
16. Koff SA, Wagner TT, Jayanthi VR. The relationship among dysfunctional elimination syndromes, primary vesicoureteral reflux and urinary tract infections in children. *J Urol* 1998;160:1019-1022.  
[http://www.ncbi.nlm.nih.gov/entrez/query.fcgi?cmd=Retrieve&db=pubmed&dopt=Abstract&list\\_uids=9719268&query\\_hl=35&itool=pubmed\\_docsum](http://www.ncbi.nlm.nih.gov/entrez/query.fcgi?cmd=Retrieve&db=pubmed&dopt=Abstract&list_uids=9719268&query_hl=35&itool=pubmed_docsum)
17. Elder JS. Guidelines for consideration for surgical repair of vesicoureteric reflux. *Curr Opin Urol* 2000;10:579-585.  
[http://www.ncbi.nlm.nih.gov/entrez/query.fcgi?cmd=Retrieve&db=pubmed&dopt=Abstract&list\\_uids=11148729&query\\_hl=7&itool=pubmed\\_docsum](http://www.ncbi.nlm.nih.gov/entrez/query.fcgi?cmd=Retrieve&db=pubmed&dopt=Abstract&list_uids=11148729&query_hl=7&itool=pubmed_docsum)
18. Arant BS Jr. Medical management of mild and moderate vesicoureteral reflux: followup studies of infants and young children. A preliminary report of the Southwest Pediatric Nephrology Study Group. *J Urol* 1992;148:1683-1687.  
[http://www.ncbi.nlm.nih.gov/entrez/query.fcgi?cmd=Retrieve&db=pubmed&dopt=Abstract&list\\_uids=1433588&query\\_hl=38&itool=pubmed\\_docsum](http://www.ncbi.nlm.nih.gov/entrez/query.fcgi?cmd=Retrieve&db=pubmed&dopt=Abstract&list_uids=1433588&query_hl=38&itool=pubmed_docsum)
19. Smellie JM, Jodal U, Lax H, Mobius TT, Hirche H, Olbing H; Writing Committee, International Reflux Study in Children (European Branch). Outcome at 10 years of severe vesicoureteric reflux managed medically: report of the International Reflux Study in Children. *J Pediatr* 2001;139:656-663.  
[http://www.ncbi.nlm.nih.gov/entrez/query.fcgi?cmd=Retrieve&db=pubmed&dopt=Abstract&list\\_uids=11713442&query\\_hl=6&itool=pubmed\\_docsum](http://www.ncbi.nlm.nih.gov/entrez/query.fcgi?cmd=Retrieve&db=pubmed&dopt=Abstract&list_uids=11713442&query_hl=6&itool=pubmed_docsum)
20. Austin JC, Cooper CS. Vesicoureteral reflux: surgical approaches. *Urol Clin North Am* 2004;31:543-557.  
[http://www.ncbi.nlm.nih.gov/entrez/query.fcgi?cmd=Retrieve&db=pubmed&dopt=Abstract&list\\_uids=15313064&query\\_hl=42&itool=pubmed\\_docsum](http://www.ncbi.nlm.nih.gov/entrez/query.fcgi?cmd=Retrieve&db=pubmed&dopt=Abstract&list_uids=15313064&query_hl=42&itool=pubmed_docsum)
21. Heidenreich A, Ozgur E, Becker T, Haupt G. Surgical management of vesicoureteral reflux in pediatric patients. *World J Urol* 2004;22:96-106.  
[http://www.ncbi.nlm.nih.gov/entrez/query.fcgi?cmd=Retrieve&db=pubmed&dopt=Abstract&list\\_uids=15221260&query\\_hl=44&itool=pubmed\\_docsum](http://www.ncbi.nlm.nih.gov/entrez/query.fcgi?cmd=Retrieve&db=pubmed&dopt=Abstract&list_uids=15221260&query_hl=44&itool=pubmed_docsum)
22. Lipski BA, Mitchell ME, Burns MW. Voiding dysfunction after bilateral extravesical ureteral reimplantation. *J Urol* 1998;159:1019-1021.  
[http://www.ncbi.nlm.nih.gov/entrez/query.fcgi?cmd=Retrieve&db=pubmed&dopt=Abstract&list\\_uids=9474222&query\\_hl=46&itool=pubmed\\_docsum](http://www.ncbi.nlm.nih.gov/entrez/query.fcgi?cmd=Retrieve&db=pubmed&dopt=Abstract&list_uids=9474222&query_hl=46&itool=pubmed_docsum)
23. Janetschek G, Radmayr C, Bartsch G. Laparoscopic ureteral anti-reflux plasty reimplantation. First clinical experience. *Ann Urol (Paris)* 1995;29:101-105.  
[http://www.ncbi.nlm.nih.gov/entrez/query.fcgi?cmd=Retrieve&db=pubmed&dopt=Abstract&list\\_uids=7645993&query\\_hl=48&itool=pubmed\\_docsum](http://www.ncbi.nlm.nih.gov/entrez/query.fcgi?cmd=Retrieve&db=pubmed&dopt=Abstract&list_uids=7645993&query_hl=48&itool=pubmed_docsum)
24. El-Ghoneimi A. Paediatric laparoscopic surgery. *Curr Opin Urol* 2003;13:329-335.  
[http://www.ncbi.nlm.nih.gov/entrez/query.fcgi?cmd=Retrieve&db=pubmed&dopt=Abstract&list\\_uids=12811298&query\\_hl=51&itool=pubmed\\_docsum](http://www.ncbi.nlm.nih.gov/entrez/query.fcgi?cmd=Retrieve&db=pubmed&dopt=Abstract&list_uids=12811298&query_hl=51&itool=pubmed_docsum)

25. Chertin B, Puri P. Endoscopic management of vesicoureteral reflux: does it stand the test of time? *Eur Urol* 2002;42:598-606.  
[http://www.ncbi.nlm.nih.gov/entrez/query.fcgi?cmd=Retrieve&db=pubmed&dopt=Abstract&list\\_uids=12477657&query\\_hl=54&itool=pubmed\\_docsum](http://www.ncbi.nlm.nih.gov/entrez/query.fcgi?cmd=Retrieve&db=pubmed&dopt=Abstract&list_uids=12477657&query_hl=54&itool=pubmed_docsum)
26. Lightner DJ. Review of the available urethral bulking agents. *Curr Opin Urol* 2002;12:333-338.  
[http://www.ncbi.nlm.nih.gov/entrez/query.fcgi?cmd=Retrieve&db=pubmed&dopt=Abstract&list\\_uids=12072655&query\\_hl=57&itool=pubmed\\_docsum](http://www.ncbi.nlm.nih.gov/entrez/query.fcgi?cmd=Retrieve&db=pubmed&dopt=Abstract&list_uids=12072655&query_hl=57&itool=pubmed_docsum)
27. Elder JS, Diaz M, Caldamone AA, Cendron M, Greenfield S, Hurwitz R, Kirsch A, Koyle MA, Pope J, Shapiro E. Endoscopic therapy for vesicoureteral reflux: a meta-analysis. I. Reflux resolution and urinary tract infection. *J Urol* 2006;175:716-722.  
[http://www.ncbi.nlm.nih.gov/entrez/query.fcgi?cmd=Retrieve&db=pubmed&dopt=Abstract&list\\_uids=16407037&query\\_hl=59&itool=pubmed\\_docsum](http://www.ncbi.nlm.nih.gov/entrez/query.fcgi?cmd=Retrieve&db=pubmed&dopt=Abstract&list_uids=16407037&query_hl=59&itool=pubmed_docsum)
28. Olbing H, Smellie JM, Jodal U, Lax H. New renal scars in children with severe VUR: a 10-year study of randomized treatment. *Pediatr Nephrol* 2003;18:1128-1131.  
[http://www.ncbi.nlm.nih.gov/entrez/query.fcgi?cmd=Retrieve&db=pubmed&dopt=Abstract&list\\_uids=14523634&query\\_hl=61&itool=pubmed\\_docsum](http://www.ncbi.nlm.nih.gov/entrez/query.fcgi?cmd=Retrieve&db=pubmed&dopt=Abstract&list_uids=14523634&query_hl=61&itool=pubmed_docsum)
29. Barrias D, Lapointe S, Reddy PP, Williot P, McLorie GA, Bigli D, Khoury AE, Merguerian PA. Are postoperative studies justified after extravesical ureteral reimplantation? *J Urol* 2000;164:1064-1066.  
[http://www.ncbi.nlm.nih.gov/entrez/query.fcgi?cmd=Retrieve&db=pubmed&dopt=Abstract&list\\_uids=10958758&query\\_hl=65&itool=pubmed\\_docsum](http://www.ncbi.nlm.nih.gov/entrez/query.fcgi?cmd=Retrieve&db=pubmed&dopt=Abstract&list_uids=10958758&query_hl=65&itool=pubmed_docsum)

## 14. URINARY STONE DISEASE IN CHILDREN

### 14.1 Background

Paediatric stone disease has unique properties in both presentation and treatment in comparison to stone disease in adults. Unlike the adult population, who show a male predominance, boys and girls are affected almost equally. Most of the stones are located in the upper urinary tract. Bladder stones are still common in underdeveloped areas of the world and they are usually ammonium acid urate and uric acid stones, strongly implicating dietary factors (1,2).

The incidence and characteristics of stones show a wide geographical variation in children. Although it is generally considered to be a relatively rare disease, urinary stone disease in children is quite common in some parts of the world. Paediatric stone disease is considered to be endemic in Turkey, Pakistan and in some South Asian, African and South American states (2).

### 14.2 Stone formation mechanisms, diagnosis of causative factors and medical treatment for specific stone types

Urinary stone formation is the result of a complex process involving metabolic and anatomical factors and the presence of infection.

When the balance between stone promoters and inhibitors is distorted, stones may form in urine. Stone formation is initiated when the urine becomes critically supersaturated with respect to the corresponding stone constituent. For example, due to the presence of organic or inorganic inhibitors that change the physical properties of urine, supersaturation may take place. Also, impaired flow of urine due to an abnormal morphology may facilitate urine stasis and therefore an increase in the concentration of stone-forming substances.

Urine supersaturation of calcium oxalate, uric acid or cystine molecules may lead to stone formation. Decreased concentration of crystallization inhibitors (citrate, magnesium, pyrophosphate, macromolecules and glycosaminoglycans) may sometimes be the sole factor responsible for the formation of urinary stones. Changes in urinary pH may also affect stone formation.

#### 14.2.1 Calcium stones

Calcium stones usually occur in the form of calcium oxalate and calcium phosphate stones. The stones are usually formed either by high concentrations of calcium (hypercalciuria) and oxalate (hyperoxaluria) or by decreased concentration of inhibitors such as citrate (hypocitraturia).

*Hypercalciuria.* This is defined by a 24-hour urinary calcium excretion of more than 4 mg/kg/day in a child weighing less than 60 kg. In infants younger than 3 months, 5 mg/kg/day is considered to be the upper limit of normal for calcium excretion (3).

Hypercalciuria can be classified as idiopathic or secondary. Idiopathic hypercalciuria is diagnosed when clinical, laboratory, and radiographic investigations fail to delineate an underlying cause. Secondary hypercalciuria occurs when a known process produces excessive urinary calcium. In secondary (hypercalcaemic) hypercalciuria, a high serum calcium level may be due to increased bone resorption (hyperparathyroidism, hyperthyroidism, immobilization, acidosis, metastatic disease) or gastrointestinal hyperabsorption (hypervitaminosis D) (4).

A good screening test for hypercalciuria compares the ratio of urinary calcium to creatinine. The normal calcium-to-creatinine ratio in children is less than 0.2. If the calculated ratio is higher than 0.2, repeat testing is indicated. Neonates and infants have higher calcium excretion and lower creatinine excretion than older children (3,4). If the follow-up ratios are normal, then no additional testing for hypercalciuria is needed. However, if the ratio remains elevated, a timed 24-hour urine collection should be obtained and the calcium excretion calculated.

The 24-hour calcium excretion test is the criterion standard for the diagnosis of hypercalciuria. If calcium excretion is higher than 4 mg/kg/day (0.1 mmol/kg/day), the diagnosis of hypercalciuria is confirmed and further evaluation is warranted. Further evaluation includes serum bicarbonate, creatinine, alkaline phosphatase, calcium, magnesium, pH, and parathyroid hormone levels. Freshly voided urine should be measured for pH (3-6).

A 24-hour urine collection should also be collected for measurement of calcium, phosphorus, sodium, magnesium, citrate and oxalate. Meanwhile dietary manipulations should be tried to normalize urine calcium (6).

Initial management is always to increase fluid intake and urinary flow.

Dietary modification is a mandatory part of effective therapy. The child should be referred to a dietician to assess accurately the daily intake of calcium, animal protein, and sodium. Dietary sodium restriction is recommended, as is maintenance of calcium intake consistent with the daily needs of the child (7).

A trial of a low-calcium diet can be done transiently to determine if exogenous calcium intake is contributing to the high urinary calcium. However, great caution should be used when trying to restrict calcium intake for long periods (level of evidence: 3, grade B recommendation).

Hydrochlorothiazide and other thiazide-type diuretics may be used to treat hypercalciuria, at a dosage of 1-2 mg/kg/day (2,8) (level of evidence: 3, grade C recommendation). Citrate therapy is also useful if citrate levels are low or if hypercalciuria persists despite other therapies (2,9) (level of evidence: 4, grade C recommendation).

*Hyperoxaluria.* Oxalic acid is a metabolite excreted by the kidneys. Only 10-15% of oxalate comes from diet. Oxalate excretion varies with age. Normal school children excrete less than 50 mg/1.73 m<sup>2</sup>/day (0.55 mmol/1.73 m<sup>2</sup>/day), while infants excrete four-fold more than this amount (2,10). Hyperoxaluria may result from increased dietary intake, enteric hyperabsorption (as in short bowel syndrome) or an inborn error of metabolism. In primary hyperoxaluria, one of the two liver enzymes that play a role in the metabolism of oxalate may be deficient. In primary hyperoxaluria, there is increased deposition of calcium oxalate in the kidney and in urine. With increased deposition of calcium oxalate in the kidneys, renal failure may ensue resulting in deposition of calcium oxalate in other tissues.

The diagnosis is made based on laboratory findings of severe hyperoxaluria and clinical symptoms. The definitive diagnosis requires a liver biopsy to assay the enzyme activity.

Other forms of hyperoxaluria, as mentioned above, may be due to hyperabsorption of oxalate in inflammatory bowel syndrome, pancreatitis and short bowel syndrome. However, in the majority of children who have high levels of oxalate excretion in urine, there is no documented metabolic problem or any dietary cause, and these children are described as having idiopathic hyperoxaluria. In this situation, urine oxalate levels are elevated only mildly (level of evidence: 4, grade C recommendation).

Treatment of hyperoxaluria consists of the promotion of high urine flow and the restriction of oxalate in diet. The use of pyridoxine may be useful in reducing urine levels, especially in type I primary hyperoxaluria (2,10).

*Hypocitraturia.* Citrate is a urinary stone inhibitor. Citrate acts by binding to calcium and by directly inhibiting the growth and aggregation of calcium oxalate as well as calcium phosphate crystals. Thus, low urine citrate may be a significant cause of calcium stone disease. In adults, hypocitraturia is the excretion of citrate in urine of less than 320 mg/day (1.5 mmol/day) for adults; this value must be adjusted for children depending on body size (11,12).

Hypocitraturia usually occurs in the absence of any concurrent symptoms or any known metabolic derangements. It may also occur in association with any metabolic acidosis, distal tubular acidosis or diarrhoeal syndromes.

Environmental factors that lower urinary citrate include a high protein intake and excessive salt intake. Many reports emphasize the significance of hypocitraturia in paediatric calcium stone disease. The presence of

hypocitraturia ranges from 30% to 60% in children with calcium stone disease.

Due to the increased stone risk in hypocitraturia, restoration of normal citrate levels is advocated to reduce stone formation. Although some studies show that citrate replacement therapy reduces stone formation risk in an adult population, there are few relevant studies in children. Hypocitraturia is treated by potassium citrate at a starting dose of 1 mEq/kg given in two divided doses (12) (level of evidence: 3, grade B recommendation).

#### 14.2.2 Uric acid stones

Uric acid is the end product of purine metabolism. Uric acid stones are responsible for urinary calculi in 4-8% of children, with hyperuricosuria being the main cause of uric acid stone formation in children. Daily output of uric acid of more than 10 mg/kg/day (0.06 mmol/kg/day) is considered to be hyperuricosuria (2).

The formation of uric acid stones is dependent mainly on the presence of acidic urinary composition. Uric acid remains in a non-dissociated and insoluble form at pH < 5.8. As the pH becomes more alkaline, uric acid crystals become more soluble and the risk of uric acid stone formation is reduced.

In the familial or idiopathic form of hyperuricosuria, children usually have normal serum uric acid levels. In other affected children, hyperuricosuria can be caused by uric acid overproduction secondary to inborn errors of metabolism, myeloproliferative disorders or other causes of cell breakdown. Although hyperuricosuria is a risk factor for calcium oxalate stone formation in adults, this does not appear to be a significant risk factor in children.

Uric acid stones are non-opaque stones and plain radiographs are insufficient for uric acid stones. Renal sonography and spiral CT are used for diagnosis.

Alkalinization of urine is the mainstay of prevention for uric acid stones. Citrate preparations are useful as alkalinizing agents. Maintaining a urine pH of 6-6.5 is sufficient for prevention of uric acid stones (2).

#### 14.2.3 Cystine stones

Cystinuria is the cause of cystine stone formation and accounts for 2-6% of all urinary stones in children. Cystinuria is an incompletely recessive autosomal disorder characterized by failure of renal tubules to reabsorb four basic amino acids:

- cystine
- ornithine
- lysine
- arginine.

Of these amino acids, only cystine has poor solubility in urine, so that only cystine stones may form in the case of excessive excretion in urine. Cystine solubility is pH-dependent, with cystine precipitation beginning at pH levels < 7.0. Other metabolic conditions, such as hypercalciuria, hypocitraturia and hyperuricosuria, may accompany cystinuria, so leading to the formation of mixed-composition stones.

Cystine stones are faintly radiopaque and may be difficult to show on regular radiograph studies. They are also hard in texture and more difficult to disintegrate by extracorporeal shockwave lithotripsy (ESWL).

The medical treatment for cystine stones aims to reduce cystine saturation in urine and increase its solubility. The initial treatment consists of maintaining a high urine flow and the use of alkalinizing agents, such as potassium citrate to maintain urine pH at above 7.0. If this treatment fails, the use of  $\alpha$ -mercaptopyrionil glycine or D-penicillamine may reduce cystine levels in urine and prevent stone formation. Use of these drugs can be associated with severe side effects, such as bone marrow depression and nephrotic syndrome (13) (level of evidence: 4, grade C recommendation).

#### 14.2.4 Infection stones (struvite stones)

Infection-related stones constitute nearly 5% of urinary stones in children. Bacteria capable of producing urease enzyme (*Proteus*, *Klebsiella*, *Pseudomonas*) are responsible for the formation of such stones. Urease converts urea into ammonia and bicarbonate, so alkalinizing the urine and further converting bicarbonate into carbonate. In the alkaline environment, triple phosphates form, eventually resulting in a supersaturated environment of magnesium ammonium phosphate and carbonate apatite, which in turn leads to stone formation.

In addition to bacterial elimination, stone elimination is essential for treatment, as stones will harbour infection and antibiotic treatment will not be effective. Consideration should be given to investigating any congenital problem that causes stasis and infection. Genitourinary tract anomalies predispose to formation of such stones.

### 14.3 Clinical presentation and diagnosis of urinary stone disease

Presentation tends to be age-dependent, with symptoms such as flank pain and haematuria being more common in older children. Non-specific symptoms (e.g. irritability, vomiting) are common in very young

children. Haematuria, usually gross, occurring with or without pain, is less common in children. However, microscopic haematuria may be the sole indicator and is more common in children. In some cases, urinary infection may be the only finding leading to radiological imaging in which a stone is identified (14,15).

## **14.4 Diagnosis**

### *14.4.1 Imaging*

Generally, ultrasonography should be used as a first study. Renal ultrasonography is very effective for identifying stones in the kidney. Many radiopaque stones can be identified with a simple abdominal flat-plate examination. If no stone is found but symptoms persist, spiral CT scanning is indicated. The most sensitive test for identifying stones in the urinary system is non-contrast helical CT scanning. It is safe and rapid, with 97% sensitivity and 96% specificity (16-18) (level of evidence: 2, grade B recommendation). Intravenous pyelography is rarely used in children, but may be needed to delineate the calyceal anatomy prior to percutaneous or open surgery.

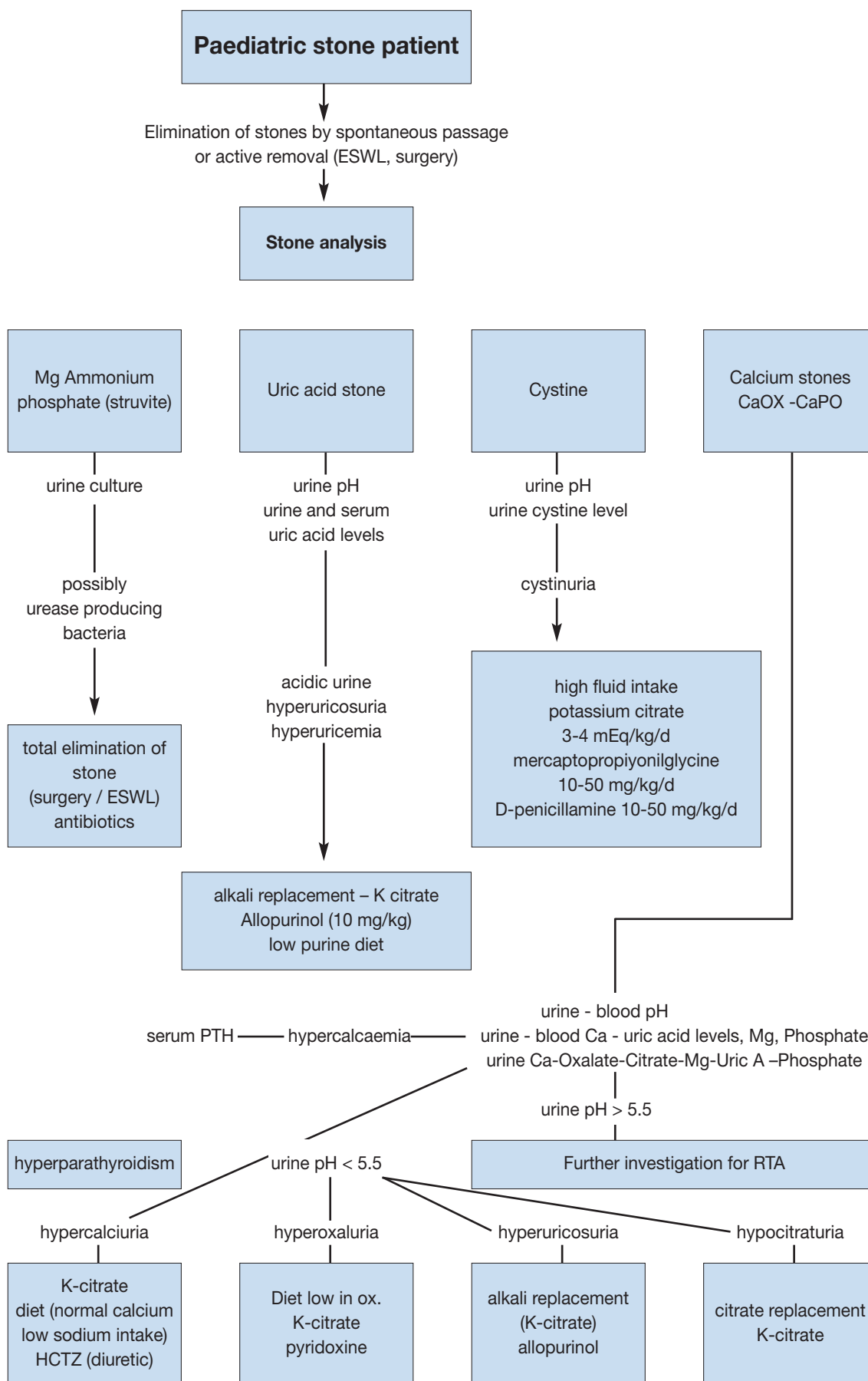
### *14.4.2 Metabolic evaluation*

Due to the high incidence of predisposing factors for urolithiasis in children and high recurrence rates, a complete metabolic evaluation of every child with urinary stone should be done (1,19,20). Metabolic evaluation includes:

- family and patient history of metabolic problems.
- analysis of stone composition (following stone analysis, metabolic evaluation can be modified according to the specific stone type).
- electrolytes, BUN, creatinine, calcium, phosphorus, alkaline phosphatase, uric acid, total protein, bicarbonate, albumin, parathyroid hormone (if there is hypercalcaemia).
- spot urinalysis and culture, including ratio of calcium to creatinine.
- urine tests, including a 24-hour urine collection for calcium, phosphorus, magnesium, oxalate, uric acid citrate, cystine, protein, and creatinine clearance.

Figure 3 provides an algorithm of how to perform metabolic investigations in urinary stone disease in children and to plan medical treatment accordingly.

**Figure 3. An algorithm providing information on performing metabolic investigations and planning medical treatment.**



ESWL = extracorporeal shockwave lithotripsy; HCTZ = hydrochlorothiazide; PTH = parathyroid hormone; RTA = renal tubular acidosis

## 14.5 Management

### 14.5.1 Surgical management of urinary stones

Due to technological advances, stone management has changed from an open surgical approach to endoscopic techniques that are less invasive. Deciding the form of treatment depends on the number, size, location, composition and anatomy of the urinary tract.

Currently, the majority of paediatric stones can easily be managed by ESWL. Endoscopic treatment can easily be applied to ureteric and bladder stones. The percutaneous removal of stones is also possible for kidney stones in children. Thus, only a small proportion of children are likely to require an open surgical approach (19,21,22).

### 14.5.2 Extracorporeal shockwave lithotripsy (ESWL)

Extracorporeal shockwave lithotripsy is an effective treatment in children with a stone-free rate of 90% and above. Some patients may need more than one session of treatment.

Currently, concerns over the risk of injury to immature kidney and bone tissue have disappeared as several animal studies have shown that renal growth and function is not significantly altered after ESWL. The success rate of ESWL has also been found to be similar to adults' success rates. In different studies, success rates range from 60% to nearly 100% and depend mainly on the stone size, location, composition and type of machines used. With smaller stone sizes, the success rates are much better.

An ideal case for ESWL treatment would be a stone less than 2 cm located in the renal pelvis. Larger stones, stones located in calyces or in anatomically abnormal kidneys are harder to clear after ESWL treatment (level of evidence: 2, grade B recommendation). As suspected initially by most clinicians, stone passage down the ureter in children has not proven to be much more difficult than in adults. However, with a large stone burden, the risk of having stone street and urinary obstruction may be high in children and children should be followed more closely for the risk of prolonged urinary tract obstruction after ESWL. There may be a need for post-ESWL stent or nephrostomy tube placement in case of prolonged obstruction.

The type of ESWL machine used strongly affects success rates and complications. The first-generation machines were able to deliver more energy to a larger focal zone, so that the fragmentation rates in a single therapy were therefore higher. However, general anaesthesia was usually required because of the discomfort caused by first-generation machines. With later generations of machines, the focal zone and energy delivered were smaller and carried less risk for pulmonary trauma. Although there may be a need for additional treatments with these machines, there are fewer requirements for anaesthesia. Except for older children, there remains a need to sedate children to make them stand still during ESWL treatment (23-28).

Extracorporeal shock wave lithotripsy can also be used for treatment of ureteral calculi. The success rates decrease for distal ureteric stones. There may be technical problems with localization and focusing of ureteric stones in children (29,30).

### 14.5.3 Percutaneous nephrolithotomy

Although ESWL is the first choice for many renal stones, percutaneous renal surgery can be applied to larger and complex stones in the kidney. The same techniques are used in children as in adults. Smaller size instruments are available for small children. Age does not seem to be a major limitation. Stone-free rates of about 90% have been reported in many series with this technique. There have been no significant complications reported, though some patients have needed a secondary look through a pre-existing nephrostomy tube (31-34) (level of evidence: 2, grade B recommendation).

### 14.5.4 Ureterorenoscopy

With the increasing availability of smaller size endourological equipment, it has become possible for paediatric ureteral stones to be managed by endoscopic techniques. It has been possible to carry out ureteroscopy in children using an 11.5F ureteroscope, while the availability of 8.5F ureteroscopes has made the use of endoscopic techniques much easier in children.

In some children, ureteric dilatation may be necessary before introducing the endoscope into the ureter. Different lithotripsy techniques, including ultrasonic, pneumatic and laser lithotripsy, have all been shown to be safe and effective (level of evidence: 2, grade B recommendation).

All studies reporting the use of endoscopy for ureteric stones in children have clearly demonstrated that there is no significant risk of ureteric strictures or reflux with this mode of therapy (35,36).

### 14.5.5 Open stone surgery

Most stones occurring in children can be managed by ESWL and endoscopic techniques. Yet, in some situations, open surgery would be obviated. Very young children with large stones and/or a congenitally obstructed system, which also requires surgical correction, are good candidates for open stone surgery. Severe

orthopaedic deformities may limit positioning for endoscopic procedures, so that open surgery would also be necessary for such children.

Bladder stones in children can usually be managed by endoscopic techniques. For very large bladder stones or for bladder stones due to an anatomical problem, open surgery may also be applied.

#### 14.6 REFERENCES

1. Straub M, Strohmaier WL, Berg W, Beck B, Hoppe B, Laube N, Lahme S, Schmidt M, Hesse A, Koehrmann KU. Diagnosis and metaphylaxis of stone disease. Consensus concept of the National Working Committee on Stone Disease for the Upcoming German Urolithiasis Guideline. *World J Urol* 2005;23:309-323.  
[http://www.ncbi.nlm.nih.gov/entrez/query.fcgi?cmd=Retrieve&db=pubmed&dopt=Abstract&list\\_uids=16315051&query\\_hl=122&itool=pubmed\\_docsum](http://www.ncbi.nlm.nih.gov/entrez/query.fcgi?cmd=Retrieve&db=pubmed&dopt=Abstract&list_uids=16315051&query_hl=122&itool=pubmed_docsum)
2. Bartosh SM. Medical management of pediatric stone disease. *Urol Clin North Am* 2004;31:575-587, x-xi.  
[http://www.ncbi.nlm.nih.gov/entrez/query.fcgi?cmd=Retrieve&db=pubmed&dopt=Abstract&list\\_uids=15313066&query\\_hl=138&itool=pubmed\\_docsum](http://www.ncbi.nlm.nih.gov/entrez/query.fcgi?cmd=Retrieve&db=pubmed&dopt=Abstract&list_uids=15313066&query_hl=138&itool=pubmed_docsum)
3. Kruse K, Kracht U, Kruse U. Reference values for urinary calcium excretion and screening for hypercalciuria in children and adolescents. *Eur J Pediatr* 1984;143:23-31.  
[http://www.ncbi.nlm.nih.gov/entrez/query.fcgi?cmd=Retrieve&db=pubmed&dopt=Abstract&list\\_uids=6510426&query\\_hl=8&itool=pubmed\\_docsum](http://www.ncbi.nlm.nih.gov/entrez/query.fcgi?cmd=Retrieve&db=pubmed&dopt=Abstract&list_uids=6510426&query_hl=8&itool=pubmed_docsum)
4. Sargent JD, Stukel TA, Kresel J, Klein RZ. Normal values for random urinary calcium to creatinine ratios in infancy. *J Pediatr* 1993;123:393-397.  
[http://www.ncbi.nlm.nih.gov/entrez/query.fcgi?cmd=Retrieve&db=pubmed&dopt=Abstract&list\\_uids=8355114&query\\_hl=6&itool=pubmed\\_docsum](http://www.ncbi.nlm.nih.gov/entrez/query.fcgi?cmd=Retrieve&db=pubmed&dopt=Abstract&list_uids=8355114&query_hl=6&itool=pubmed_docsum)
5. Stapleton FB, Noe HN, Roy S 3rd, Jerkins GR. Hypercalciuria in children with urolithiasis. *Am J Dis Child* 1982;136:675-678.  
[http://www.ncbi.nlm.nih.gov/entrez/query.fcgi?cmd=Retrieve&db=pubmed&dopt=Abstract&list\\_uids=7102617&query\\_hl=3&itool=pubmed\\_docsum](http://www.ncbi.nlm.nih.gov/entrez/query.fcgi?cmd=Retrieve&db=pubmed&dopt=Abstract&list_uids=7102617&query_hl=3&itool=pubmed_docsum)
6. Stapleton FB, Noe HN, Roy S 3rd, Jerkins GR. Urinary excretion of calcium following an oral calcium loading test in healthy children. *Pediatrics* 1982;69:594-597.  
[http://www.ncbi.nlm.nih.gov/entrez/query.fcgi?cmd=Retrieve&db=pubmed&dopt=Abstract&list\\_uids=7079015&query\\_hl=3&itool=pubmed\\_docsum](http://www.ncbi.nlm.nih.gov/entrez/query.fcgi?cmd=Retrieve&db=pubmed&dopt=Abstract&list_uids=7079015&query_hl=3&itool=pubmed_docsum)
7. Borghi L, Schianchi T, Meschi T, Guerra A, Allegri F, Maggiore U, Novarini A. Comparison of two diets for the prevention of recurrent stones in idiopathic hypercalciuria. *N Engl J Med* 2002;346:77-84.  
[http://www.ncbi.nlm.nih.gov/entrez/query.fcgi?cmd=Retrieve&db=pubmed&dopt=Abstract&list\\_uids=11784873&query\\_hl=118&itool=pubmed\\_docsum](http://www.ncbi.nlm.nih.gov/entrez/query.fcgi?cmd=Retrieve&db=pubmed&dopt=Abstract&list_uids=11784873&query_hl=118&itool=pubmed_docsum)
8. Preminger GM, Pak CY. Eventual attenuation of hypocalciuric response to hydrochlorothiazide in absorptive hypercalciuria. *J Urol* 1987;137:1104-1108.  
[http://www.ncbi.nlm.nih.gov/entrez/query.fcgi?cmd=Retrieve&db=pubmed&dopt=Abstract&list\\_uids=3586136&query\\_hl=10&itool=pubmed\\_docsum](http://www.ncbi.nlm.nih.gov/entrez/query.fcgi?cmd=Retrieve&db=pubmed&dopt=Abstract&list_uids=3586136&query_hl=10&itool=pubmed_docsum)
9. Tekin A, Tekgul S, Atsu N, Bakkaloglu M, Kendi S. Oral potassium citrate treatment for idiopathic hypocitruria in children with calcium urolithiasis. *J Urol* 2002;168:2572-2574.  
[http://www.ncbi.nlm.nih.gov/entrez/query.fcgi?cmd=Retrieve&db=pubmed&dopt=Abstract&list\\_uids=12441986&query\\_hl=146&itool=pubmed\\_docsum](http://www.ncbi.nlm.nih.gov/entrez/query.fcgi?cmd=Retrieve&db=pubmed&dopt=Abstract&list_uids=12441986&query_hl=146&itool=pubmed_docsum)
10. Morgenstern BZ, Milliner DS, Murphy ME, Simmons PS, Moyer TP, Wilson DM, Smith LH. Urinary oxalate and glycolate excretion patterns in the first year of life: a longitudinal study. *J Pediatr* 1993;123:248-51.  
[http://www.ncbi.nlm.nih.gov/entrez/query.fcgi?cmd=Retrieve&db=PubMed&list\\_uids=8345420&dopt=Abstract](http://www.ncbi.nlm.nih.gov/entrez/query.fcgi?cmd=Retrieve&db=PubMed&list_uids=8345420&dopt=Abstract)
11. Defoor W, Asplin J, Jackson E, Jackson C, Reddy P, Sheldon C, Minevich E. Results of a prospective trial to compare normal urine supersaturation in children and adults. *J Urol* 2005;174:1708-1710.  
[http://www.ncbi.nlm.nih.gov/entrez/query.fcgi?cmd=Retrieve&db=pubmed&dopt=Abstract&list\\_uids=16148687&query\\_hl=126&itool=pubmed\\_docsum](http://www.ncbi.nlm.nih.gov/entrez/query.fcgi?cmd=Retrieve&db=pubmed&dopt=Abstract&list_uids=16148687&query_hl=126&itool=pubmed_docsum)
12. Tekin A, Tekgul S, Atsu N, Sahin A, Ozen H, Bakkaloglu M. A study of the etiology of idiopathic calcium urolithiasis in children: hypocitruria is the most important risk factor. *J Urol* 2000;164:162-165.  
[http://www.ncbi.nlm.nih.gov/entrez/query.fcgi?cmd=Retrieve&db=pubmed&dopt=Abstract&list\\_uids=10840454&query\\_hl=128&itool=pubmed\\_docsum](http://www.ncbi.nlm.nih.gov/entrez/query.fcgi?cmd=Retrieve&db=pubmed&dopt=Abstract&list_uids=10840454&query_hl=128&itool=pubmed_docsum)
13. Tekin A, Tekgul S, Atsu N, Sahin A, Bakkaloglu M. Cystine calculi in children: the results of a metabolic evaluation and response to medical therapy. *J Urol* 2001;165:2328-2330.  
[http://www.ncbi.nlm.nih.gov/entrez/query.fcgi?cmd=Retrieve&db=pubmed&dopt=Abstract&list\\_uids=11371943&query\\_hl=150&itool=pubmed\\_docsum](http://www.ncbi.nlm.nih.gov/entrez/query.fcgi?cmd=Retrieve&db=pubmed&dopt=Abstract&list_uids=11371943&query_hl=150&itool=pubmed_docsum)



14. Bove P, Kaplan D, Dalrymple N, Rosenfield AT, Verga M, Anderson K, Smith RC. Reexamining the value of hematuria testing in patients with acute flank pain. *J Urol* 1999;162:685-687.  
[http://www.ncbi.nlm.nih.gov/entrez/query.fcgi?cmd=Retrieve&db=pubmed&dopt=Abstract&list\\_uids=10458342&query\\_hl=120&itool=pubmed\\_docsum](http://www.ncbi.nlm.nih.gov/entrez/query.fcgi?cmd=Retrieve&db=pubmed&dopt=Abstract&list_uids=10458342&query_hl=120&itool=pubmed_docsum)
15. Sternberg K, Greenfield SP, Williot P, Wan J. Pediatric stone disease: an evolving experience. *J Urol* 2005;174:1711-1714  
[http://www.ncbi.nlm.nih.gov/entrez/query.fcgi?cmd=Retrieve&db=pubmed&dopt=Abstract&list\\_uids=16148688&query\\_hl=124&itool=pubmed\\_docsum](http://www.ncbi.nlm.nih.gov/entrez/query.fcgi?cmd=Retrieve&db=pubmed&dopt=Abstract&list_uids=16148688&query_hl=124&itool=pubmed_docsum)
16. Oner S, Oto A, Tekgul S, Koroglu M, Hascicek M, Sahin A, Akhan O. Comparison of spiral CT and US in the evaluation of paediatric urolithiasis. *JBR-BTR* 2004;87:219-223.  
[http://www.ncbi.nlm.nih.gov/entrez/query.fcgi?cmd=Retrieve&db=pubmed&dopt=Abstract&list\\_uids=15587558&query\\_hl=160&itool=pubmed\\_docsum](http://www.ncbi.nlm.nih.gov/entrez/query.fcgi?cmd=Retrieve&db=pubmed&dopt=Abstract&list_uids=15587558&query_hl=160&itool=pubmed_docsum)
17. Memarsadeghi M, Heinz-Peer G, Helbich TH, Schaefer-Prokop C, Kramer G, Scharitzer M, Prokop M. Unenhanced multi-detector row CT in patients suspected of having urinary stone disease: effect of section width on diagnosis. *Radiology* 2005;235:530-536.  
[http://www.ncbi.nlm.nih.gov/entrez/query.fcgi?cmd=Retrieve&db=pubmed&dopt=Abstract&list\\_uids=15758192&query\\_hl=134&itool=pubmed\\_docsum](http://www.ncbi.nlm.nih.gov/entrez/query.fcgi?cmd=Retrieve&db=pubmed&dopt=Abstract&list_uids=15758192&query_hl=134&itool=pubmed_docsum)
18. Strouse PJ, Bates DG, Bloom DA, Goodsitt MM. Non-contrast thin-section helical CT of urinary tract calculi in children. *Pediatr Radiol* 2002;32:326-332.  
[http://www.ncbi.nlm.nih.gov/entrez/query.fcgi?cmd=Retrieve&db=pubmed&dopt=Abstract&list\\_uids=11956719&query\\_hl=156&itool=pubmed\\_docsum](http://www.ncbi.nlm.nih.gov/entrez/query.fcgi?cmd=Retrieve&db=pubmed&dopt=Abstract&list_uids=11956719&query_hl=156&itool=pubmed_docsum)
19. Tiselius HG, Ackermann D, Alken P, Buck C, Conort P, Gallucci M; Working Party on Lithiasis, European Association of Urology. Guidelines on urolithiasis. *Eur Urol*;40:362-371.  
[http://www.ncbi.nlm.nih.gov/entrez/query.fcgi?cmd=Retrieve&db=pubmed&dopt=Abstract&list\\_uids=11713390&query\\_hl=4&itool=pubmed\\_docsum](http://www.ncbi.nlm.nih.gov/entrez/query.fcgi?cmd=Retrieve&db=pubmed&dopt=Abstract&list_uids=11713390&query_hl=4&itool=pubmed_docsum)
20. Tekin A, Tekgul S, Atsu N, Ergen A, Kendi S. Ureteropelvic junction obstruction and coexisting renal calculi in children: role of metabolic abnormalities. *Urology* 2001;57:542-545.  
[http://www.ncbi.nlm.nih.gov/entrez/query.fcgi?cmd=Retrieve&db=pubmed&dopt=Abstract&list\\_uids=11248635&query\\_hl=150&itool=pubmed\\_docsum](http://www.ncbi.nlm.nih.gov/entrez/query.fcgi?cmd=Retrieve&db=pubmed&dopt=Abstract&list_uids=11248635&query_hl=150&itool=pubmed_docsum)
21. Raza A, Turna B, Smith G, Moussa S, Tolley DA. Paediatric urolithiasis: 15 years of local experience with minimally invasive endourological management of paediatric calculi. *J Urol* 2005;174:682-685.  
[http://www.ncbi.nlm.nih.gov/entrez/query.fcgi?cmd=Retrieve&db=pubmed&dopt=Abstract&list\\_uids=16006948&query\\_hl=132&itool=pubmed\\_docsum](http://www.ncbi.nlm.nih.gov/entrez/query.fcgi?cmd=Retrieve&db=pubmed&dopt=Abstract&list_uids=16006948&query_hl=132&itool=pubmed_docsum)
22. Rizvi SA, Naqvi SA, Hussain Z, Hashmi A, Hussain M, Zafar MN, Sultan S, Mehdi H. Paediatric urolithiasis: developing nation perspectives. *J Urol* 2002;168:1522-1525.  
[http://www.ncbi.nlm.nih.gov/entrez/query.fcgi?cmd=Retrieve&db=pubmed&dopt=Abstract&list\\_uids=12352448&query\\_hl=148&itool=pubmed\\_docsum](http://www.ncbi.nlm.nih.gov/entrez/query.fcgi?cmd=Retrieve&db=pubmed&dopt=Abstract&list_uids=12352448&query_hl=148&itool=pubmed_docsum)
23. Aksoy Y, Ozbey I, Atmaca AF, Polat O. Extracorporeal shock wave lithotripsy in children: experience using a mpl-9000 lithotripter. *World J Urol* 2004;22:115-119.  
[http://www.ncbi.nlm.nih.gov/entrez/query.fcgi?cmd=Retrieve&db=pubmed&dopt=Abstract&list\\_uids=14740160&query\\_hl=142&itool=pubmed\\_docsum](http://www.ncbi.nlm.nih.gov/entrez/query.fcgi?cmd=Retrieve&db=pubmed&dopt=Abstract&list_uids=14740160&query_hl=142&itool=pubmed_docsum)
24. Vljakovic M, Slavkovic A, Radovanovic M, Siric Z, Stefanovic V, Perovic S. Long-term functional outcome of kidneys in children with urolithiasis after ESWL treatment. *Eur J Pediatr Surg* 2002;12:118-123.  
[http://www.ncbi.nlm.nih.gov/entrez/query.fcgi?cmd=Retrieve&db=pubmed&dopt=Abstract&list\\_uids=12015657&query\\_hl=153&itool=pubmed\\_docsum](http://www.ncbi.nlm.nih.gov/entrez/query.fcgi?cmd=Retrieve&db=pubmed&dopt=Abstract&list_uids=12015657&query_hl=153&itool=pubmed_docsum)
25. Afshar K, McLorie G, Papanikolaou F, Malek R, Harvey E, Pippi-Salle JL, Bagli DJ, Khoury AE, Farhat W. Outcome of small residual stone fragments following shock wave lithotripsy in children. *J Urol* 2004;172:1600-1603.  
[http://www.ncbi.nlm.nih.gov/entrez/query.fcgi?cmd=Retrieve&db=pubmed&dopt=Abstract&list\\_uids=15371769&query\\_hl=164&itool=pubmed\\_docsum](http://www.ncbi.nlm.nih.gov/entrez/query.fcgi?cmd=Retrieve&db=pubmed&dopt=Abstract&list_uids=15371769&query_hl=164&itool=pubmed_docsum)
26. Tan AH, Al-Omar M, Watterson JD, Nott L, Denstedt JD, Razvi H. Results of shockwave lithotripsy for pediatric urolithiasis. *J Endourol* 2004;18:527-530.  
[http://www.ncbi.nlm.nih.gov/entrez/query.fcgi?cmd=Retrieve&db=pubmed&dopt=Abstract&list\\_uids=15333214&query\\_hl=169&itool=pubmed\\_docsum](http://www.ncbi.nlm.nih.gov/entrez/query.fcgi?cmd=Retrieve&db=pubmed&dopt=Abstract&list_uids=15333214&query_hl=169&itool=pubmed_docsum)
27. Al-Busaidy SS, Prem AR, Medhat M. Pediatric staghorn calculi: the role of extracorporeal shock wave lithotripsy monotherapy with special reference to ureteral stenting. *J Urol* 2003;169:629-633.  
[http://www.ncbi.nlm.nih.gov/entrez/query.fcgi?cmd=Retrieve&db=pubmed&dopt=Abstract&list\\_uids=12544330&query\\_hl=173&itool=pubmed\\_docsum](http://www.ncbi.nlm.nih.gov/entrez/query.fcgi?cmd=Retrieve&db=pubmed&dopt=Abstract&list_uids=12544330&query_hl=173&itool=pubmed_docsum)

28. Lottmann HB, Traxer O, Archambaud F, Mercier-Pageyral B. Monotherapy extracorporeal shock wave lithotripsy for the treatment of staghorn calculi in children. *J Urol* 2001;165:2324-2327.  
[http://www.ncbi.nlm.nih.gov/entrez/query.fcgi?cmd=Retrieve&db=pubmed&dopt=Abstract&list\\_uids=11371942&query\\_hl=175&itool=pubmed\\_docsum](http://www.ncbi.nlm.nih.gov/entrez/query.fcgi?cmd=Retrieve&db=pubmed&dopt=Abstract&list_uids=11371942&query_hl=175&itool=pubmed_docsum)
29. Ozgur Tan M, Karaoglan U, Sozen S, Bozkirli I. Extracorporeal shock-wave lithotripsy for treatment of ureteral calculi in paediatric patients. *Pediatr Surg Int* 2003;19:471-474.  
[http://www.ncbi.nlm.nih.gov/entrez/query.fcgi?cmd=Retrieve&db=pubmed&dopt=Abstract&list\\_uids=12736749&query\\_hl=144&itool=pubmed\\_docsum](http://www.ncbi.nlm.nih.gov/entrez/query.fcgi?cmd=Retrieve&db=pubmed&dopt=Abstract&list_uids=12736749&query_hl=144&itool=pubmed_docsum)
30. Hochreiter WW, Danuser H, Perrig M, Studer UE. Extracorporeal shock wave lithotripsy for distal ureteral calculi: what a powerful machine can achieve. *J Urol* 2003;169:878-880.  
[http://www.ncbi.nlm.nih.gov/entrez/query.fcgi?cmd=Retrieve&db=pubmed&dopt=Abstract&list\\_uids=12576804&query\\_hl=171&itool=pubmed\\_docsum](http://www.ncbi.nlm.nih.gov/entrez/query.fcgi?cmd=Retrieve&db=pubmed&dopt=Abstract&list_uids=12576804&query_hl=171&itool=pubmed_docsum)
31. Sahin A, Tekgul S, Erdem E, Ekici S, Hascicek M, Kendi S. Percutaneous nephrolithotomy in older children. *J Pediatr Surg* 2000;35:1336-1338.  
[http://www.ncbi.nlm.nih.gov/entrez/query.fcgi?cmd=Retrieve&db=pubmed&dopt=Abstract&list\\_uids=10999692&query\\_hl=158&itool=pubmed\\_docsum](http://www.ncbi.nlm.nih.gov/entrez/query.fcgi?cmd=Retrieve&db=pubmed&dopt=Abstract&list_uids=10999692&query_hl=158&itool=pubmed_docsum)
32. Shokeir AA, El-Nahas AR, Shoma AM, Eraky I, El-Kenawy M, Mokhtar A, El-Kappany H. Percutaneous nephrolithotomy in treatment of large stones within horseshoe kidneys. *Urology* 2004;64:426-429.  
[http://www.ncbi.nlm.nih.gov/entrez/query.fcgi?cmd=Retrieve&db=pubmed&dopt=Abstract&list\\_uids=15351557&query\\_hl=166&itool=pubmed\\_docsum](http://www.ncbi.nlm.nih.gov/entrez/query.fcgi?cmd=Retrieve&db=pubmed&dopt=Abstract&list_uids=15351557&query_hl=166&itool=pubmed_docsum)
33. Boormans JL, Scheepe JR, Verkoelen CF, Verhagen PC. Percutaneous nephrolithotomy for treating renal calculi in children. *BJU Int* 2005;95:631-634.  
[http://www.ncbi.nlm.nih.gov/entrez/query.fcgi?cmd=Retrieve&db=pubmed&dopt=Abstract&list\\_uids=15705093&query\\_hl=136&itool=pubmed\\_docsum](http://www.ncbi.nlm.nih.gov/entrez/query.fcgi?cmd=Retrieve&db=pubmed&dopt=Abstract&list_uids=15705093&query_hl=136&itool=pubmed_docsum)
34. Desai MR, Kukreja RA, Patel SH, Bapat SD. Percutaneous nephrolithotomy for complex paediatric renal calculus disease. *J Endourol* 2004;18:23-27.  
[http://www.ncbi.nlm.nih.gov/entrez/query.fcgi?cmd=Retrieve&db=pubmed&dopt=Abstract&list\\_uids=15006048&query\\_hl=140&itool=pubmed\\_docsum](http://www.ncbi.nlm.nih.gov/entrez/query.fcgi?cmd=Retrieve&db=pubmed&dopt=Abstract&list_uids=15006048&query_hl=140&itool=pubmed_docsum)
35. Dogan HS, Tekgul S, Akdogan B, Keskin MS, Sahin A. Use of the holmium:YAG laser for ureterolithotripsy in children. *BJU Int* 2004;94:131-133.  
[http://www.ncbi.nlm.nih.gov/entrez/query.fcgi?cmd=Retrieve&db=pubmed&dopt=Abstract&list\\_uids=15217447&query\\_hl=162&itool=pubmed\\_docsum](http://www.ncbi.nlm.nih.gov/entrez/query.fcgi?cmd=Retrieve&db=pubmed&dopt=Abstract&list_uids=15217447&query_hl=162&itool=pubmed_docsum)
36. Thomas JC, DeMarco RT, Donohoe JM, Adams MC, Brock JW 3rd, Pope JC 4th. Paediatric ureteroscopic stone management. *J Urol* 2005;174:1072-1074.  
[http://www.ncbi.nlm.nih.gov/entrez/query.fcgi?cmd=Retrieve&db=pubmed&dopt=Abstract&list\\_uids=16094060&query\\_hl=130&itool=pubmed\\_docsum](http://www.ncbi.nlm.nih.gov/entrez/query.fcgi?cmd=Retrieve&db=pubmed&dopt=Abstract&list_uids=16094060&query_hl=130&itool=pubmed_docsum)

## 15. OBSTRUCTIVE PATHOLOGY OF RENAL DUPLICATION: URETEROCELE AND EXTOPIC URETER

### 15.1 Background

Ureterocele and ectopic ureter are the two main anomalies associated with a complete renal duplication. At present, antenatal ultrasonography detects both conditions in the majority of cases and diagnosis is confirmed after birth by further examination. Later on in life, these anomalies are revealed by clinical symptoms: UTI, pain, disturbances of micturition and urinary incontinence.

#### 15.1.1 Ureterocele

Ureterocele is a cystic dilatation developed on the intravesical part of the ureter corresponding to the upper pole of a renal duplication. It is more frequent in females than in males, the overall prevalence being 1 in 4,000 births.

#### 15.1.2 Ectopic ureter

Ectopic ureter is less frequent than ureterocele (1 in 40,000 births), but is again more common in females (male

to female ratio, 1:5). Eighty per cent of ectopic ureters are associated with a complete renal duplication.

In females, the ureteral orifice may be located:

- in the urethra, from bladder neck to meatus (35%)
- in the vaginal vestibule (30%)
- in the vagina (25%)
- in the uterus and Fallopian tube (rarely).

In males, the ureteral orifice may be located:

- in the posterior urethra above the verumontanum and never below the external sphincter (60%)
- in the seminal tract (vas deferens, ejaculatory ducts, seminal vesicles) (40%).

## 15.2 Classification

Ureterocele is usually obstructive for the upper pole moiety, but the degree of obstruction and functional impairment is variable according to the type of ureterocele and upper pole dysplasia. In the orthotopic form, there is often no, or only mild, obstruction and frequently the function of the moiety is normal or slightly impaired; the corresponding ureter may be dilated. In the ectopic form, the upper pole is altered, frequently dysplastic and hypofunctional or non-functional. The corresponding ureter is a megaureter. In the caecoureterocele (see definition below), the upper pole of the renal duplication is always dysplastic and non-functional.

### 15.2.1 Ectopic ureterocele

Ectopic ureterocele is the most common form of ureterocele (> 80%) and occurs bilaterally in about 40% of cases. It is voluminous, dissociating the trigone and slipping into the urethra, and can rarely prolapse through the urethral meatus. The ureterocele orifice is tight, rarely large, and located near the bladder neck, either in the bladder itself or in the urethra below the bladder neck. The ureter corresponding to the lower pole moiety is raised by the ureterocele and is frequently refluxing or compressed by the ureterocele, leading to an obstructive megaureter. A contralateral renal duplication is associated in 50% of cases. Occasionally, very large ureteroceles are responsible for reflux or obstruction of the contralateral upper tract.

### 15.2.2 Orthotopic ureterocele

Orthotopic ureterocele accounts for 15% of cases. It is exclusively observed in females, and is small and located strictly intravesically. Orthotopic ureteroceles are mostly combined with a single kidney system.

### 15.2.3 Caecoureterocele

Caecoureterocele is very rare, occurring in less than 5% of cases. It is associated with an ectopic ureter and located in the urethra below the bladder neck.

## 15.3 Diagnosis

### 15.3.1 Ureterocele

Prenatal ultrasound reveals easily voluminous obstructive ureteroceles. In cases of a very small upper pole or a slightly obstructive ureterocele, prenatal diagnosis will be difficult. If prenatal diagnosis has been impossible, the following clinical symptoms - beside incidental findings - can reveal the congenital anomaly at birth or later:

- at birth, a prolapsed and sometimes strangulated ureterocele may be observed in front of the urethral orifice. In a newborn boy, it might cause acute urinary retention, simulating urethral valves
- the early symptom of pyelonephritis in either sex may lead to the diagnosis
- later symptoms can include dysuria, recurrent cystitis and urgency.

In cases of prenatal diagnosis at birth, ultrasonography confirms the ureteral dilatation ending at the upper pole of a renal duplication. It also demonstrates the presence of an ureterocele in the bladder, with a dilated ureter behind the bladder.

At this point, it is important to assess the function of the upper pole using nuclear renography in the region of interest. Magnetic resonance urography may visualize the morphological status of the upper pole and lower moieties and of the contralateral kidney. A VCUG is mandatory in identifying an ipsilateral or contralateral reflux and to assess the degree of intraurethral prolapse of the ureterocele.

Urethrocystoscopy may reveal the pathology in cases where it is difficult to make the differential diagnosis between ureterocele and ectopic megaureter.

### 15.3.2 Ectopic ureter

Most of the ectopic megaureters are diagnosed primarily by ultrasound. In some cases, clinical symptoms can lead to diagnosis:

- in neonates: dribbling of urine, pyuria and acute pyelonephritis
- an ectopic orifice may be found in the meatal region. Significant vaginal discharge may be the equivalent of incontinence in little girls
- in pre-adolescent males: epididymitis is the usual clinical presentation and a palpable seminal vesicle may be found on digital rectal examination.

Ultrasonography, nuclear studies, VCUG, MR urography and cystoscopy are the diagnostic tools to assess function, to detect reflux and to rule out ipsilateral compression of the lower pole and urethral obstruction. In the clarification of incontinence in girls, a methylene blue filling of the bladder can be helpful: in the case of loss of uncoloured urine, an ectopic ureter must be present.

## 15.4 Treatment

### 15.4.1 Ureterocele

The management is controversial with the choice between endoscopic decompression, partial nephro-ureterectomy or complete primary reconstruction. The choice of a therapeutic modality depends on the following criteria: clinical status of the patient (e.g. urosepsis), age of the patient, renal function of the upper pole, presence or absence of reflux, obstruction of the ipsilateral ureter, pathology of the contralateral ureter, and parents' and surgeon's preferences.

#### 15.4.1.1 Early diagnosis

- in a clinically asymptomatic child with an ureterocele and non- or hypo-functional upper pole, without significant obstruction of the lower pole and without bladder outlet obstruction, prophylactic antibiotic treatment is given until follow-up procedures are instigated
- in the presence of severe obstruction and infection, an immediate endoscopic incision or puncture is recommended.

#### 15.4.1.2 Re-evaluation

If decompression is effective and there is no reflux (approximately 25% of cases), the patient is followed-up conservatively. Secondary surgery is necessary if decompression is not effective, significant reflux is present or there is obstruction of the ipsi- or contra-lateral ureters and/or bladder neck obstruction. Surgery may vary from partial nephrectomy to complete unilateral reconstruction.

### 15.4.2 Ectopic ureter

In the majority of cases, the upper pole is dysplastic and heminephro-ureterectomy should be considered. Ureteral reconstruction is a therapeutic option in cases in which the upper pole has function worth preserving.

## 15.5 REFERENCES

### Ureterocele

1. Austin PF, Cain MP, Casale AJ, Hiatt AK, Rink RC. Prenatal bladder outlet obstruction secondary to ureterocele. *Urology* 1998;52:1132-1135.  
[http://www.ncbi.nlm.nih.gov:80/entrez/query.fcgi?cmd=Retrieve&db=PubMed&list\\_uids=9836570&dopt=Abstract](http://www.ncbi.nlm.nih.gov:80/entrez/query.fcgi?cmd=Retrieve&db=PubMed&list_uids=9836570&dopt=Abstract)
2. Borer JG, Cisek LJ, Atala A, Diamond DA, Retik AB, Peters CA. Pediatric retroperitoneoscopic nephrectomy using 2 mm instrumentation. *J Urol* 1999;162:1725-1729; discussion 1730.  
[http://www.ncbi.nlm.nih.gov:80/entrez/query.fcgi?cmd=Retrieve&db=PubMed&list\\_uids=10524923&dopt=Abstract](http://www.ncbi.nlm.nih.gov:80/entrez/query.fcgi?cmd=Retrieve&db=PubMed&list_uids=10524923&dopt=Abstract)
3. Cain MP, Pope JC, Casale AJ, Adams MC, Keating MA, Rink RC. Natural history of refluxing distal ureteral stumps after nephrectomy and partial ureterectomy for vesicoureteral reflux. *J Urol* 1998;160:1026-1027.  
[http://www.ncbi.nlm.nih.gov:80/entrez/query.fcgi?cmd=Retrieve&db=PubMed&list\\_uids=9719270&dopt=Abstract](http://www.ncbi.nlm.nih.gov:80/entrez/query.fcgi?cmd=Retrieve&db=PubMed&list_uids=9719270&dopt=Abstract)
4. Cendron J, Melin Y, Valayer J. [Simplified treatment of ureterocele with pyeloureteric duplication. A propos of 35 cases.] *Chir Pediatr* 1980;21:121-124. [French]  
[http://www.ncbi.nlm.nih.gov:80/entrez/query.fcgi?cmd=Retrieve&db=PubMed&list\\_uids=7448978&dopt=Abstract](http://www.ncbi.nlm.nih.gov:80/entrez/query.fcgi?cmd=Retrieve&db=PubMed&list_uids=7448978&dopt=Abstract)

5. Decter RM, Roth DR, Gonzales ET. Individualized treatment of ureteroceles. *J Urol* 1989;142:535-537. [http://www.ncbi.nlm.nih.gov:80/entrez/query.fcgi?cmd=Retrieve&db=PubMed&list\\_uids=2746775&dopt=Abstract](http://www.ncbi.nlm.nih.gov:80/entrez/query.fcgi?cmd=Retrieve&db=PubMed&list_uids=2746775&dopt=Abstract)
6. Di Benedetto V, Montfort G. How prenatal ultrasound can change the treatment of ectopic ureterocele in neonates? *Eur J Pediatr Surg* 1997;7:338-340. [http://www.ncbi.nlm.nih.gov:80/entrez/query.fcgi?cmd=Retrieve&db=PubMed&list\\_uids=9493984&dopt=Abstract](http://www.ncbi.nlm.nih.gov:80/entrez/query.fcgi?cmd=Retrieve&db=PubMed&list_uids=9493984&dopt=Abstract)
7. el Ghoneimi A, Lottmann H, Odet E, Bonnin F, Aigrain Y. [Ureteropyelostomy for obstructed duplicated ureter an easy and reliable operation in infants.] *Ann Urol (Paris)* 1998;32:241-246. [French] [http://www.ncbi.nlm.nih.gov:80/entrez/query.fcgi?cmd=Retrieve&db=PubMed&list\\_uids=9791553&dopt=Abstract](http://www.ncbi.nlm.nih.gov:80/entrez/query.fcgi?cmd=Retrieve&db=PubMed&list_uids=9791553&dopt=Abstract)
8. Husmann D, Strand B, Ewalt D, Clement M, Kramer S, Allen T. Management of ectopic ureterocele associated with renal duplication: a comparison of partial nephrectomy and endoscopic decompression. *J Urol* 1999;162:1406-1409. [http://www.ncbi.nlm.nih.gov:80/entrez/query.fcgi?cmd=Retrieve&db=PubMed&list\\_uids=10492225&dopt=Abstract](http://www.ncbi.nlm.nih.gov:80/entrez/query.fcgi?cmd=Retrieve&db=PubMed&list_uids=10492225&dopt=Abstract)
9. Janetschek G, Seibold J, Radmayr C, Bartsch G. Laparoscopic heminephroureterectomy in pediatric patients. *J Urol* 1997;158:1928-1930. [http://www.ncbi.nlm.nih.gov:80/entrez/query.fcgi?cmd=Retrieve&db=PubMed&list\\_uids=9334640&dopt=Abstract](http://www.ncbi.nlm.nih.gov:80/entrez/query.fcgi?cmd=Retrieve&db=PubMed&list_uids=9334640&dopt=Abstract)
10. Jayanthi VR, Koff SA. Long-term outcome of transurethral puncture of ectopic ureteroceles: initial success and late problems. *J Urol* 1999;162:1077-1080. [http://www.ncbi.nlm.nih.gov:80/entrez/query.fcgi?cmd=Retrieve&db=PubMed&list\\_uids=10458435&dopt=Abstract](http://www.ncbi.nlm.nih.gov:80/entrez/query.fcgi?cmd=Retrieve&db=PubMed&list_uids=10458435&dopt=Abstract)
11. Moscovici J, Galinier P, Berrogain N, Juricic M. [Management of ureteroceles with pyelo-ureteral duplication in children. Report of 64 cases.] *Ann Urol (Paris)* 1999;33:369-376. [French] [http://www.ncbi.nlm.nih.gov:80/entrez/query.fcgi?cmd=Retrieve&db=PubMed&list\\_uids=10544742&dopt=Abstract](http://www.ncbi.nlm.nih.gov:80/entrez/query.fcgi?cmd=Retrieve&db=PubMed&list_uids=10544742&dopt=Abstract)
12. Monfort G, Guys JM, Coquet M, Roth K, Louis C, Bocciardi A. Surgical management of duplex ureteroceles. *J Ped Surg* 1992;27:634-638. [http://www.ncbi.nlm.nih.gov:80/entrez/query.fcgi?cmd=Retrieve&db=PubMed&list\\_uids=1625138&dopt=Abstract](http://www.ncbi.nlm.nih.gov:80/entrez/query.fcgi?cmd=Retrieve&db=PubMed&list_uids=1625138&dopt=Abstract)
13. Pfister C, Ravasse P, Barret E, Petit T, Mitrofanoff P. The value of endoscopic treatment for ureteroceles during the neonatal period. *J Urol* 1998;159:1006-1009. [http://www.ncbi.nlm.nih.gov:80/entrez/query.fcgi?cmd=Retrieve&db=PubMed&list\\_uids=9474217&dopt=Abstract](http://www.ncbi.nlm.nih.gov:80/entrez/query.fcgi?cmd=Retrieve&db=PubMed&list_uids=9474217&dopt=Abstract)
14. Rickwood AMK, Reiner I, Jones M, Pournaras C. Current management of duplex system ureteroceles: experience with 41 patients. *Br J Urol* 1992;70:196-200. [http://www.ncbi.nlm.nih.gov:80/entrez/query.fcgi?cmd=Retrieve&db=PubMed&list\\_uids=1393443&dopt=Abstract](http://www.ncbi.nlm.nih.gov:80/entrez/query.fcgi?cmd=Retrieve&db=PubMed&list_uids=1393443&dopt=Abstract)
15. Roy GT, Desai S, Cohen RC. Ureteroceles in children: an ongoing challenge. *Pediatr Surg Int* 1997; 12:44-48. [http://www.ncbi.nlm.nih.gov:80/entrez/query.fcgi?cmd=Retrieve&db=PubMed&list\\_uids=9035209&dopt=Abstract](http://www.ncbi.nlm.nih.gov:80/entrez/query.fcgi?cmd=Retrieve&db=PubMed&list_uids=9035209&dopt=Abstract)
16. Sherz HC, Kaplan GW, Packer MG, Brock WA. Ectopic ureteroceles: surgical management with preservation of continence - review of 60 cases. *J Urol* 1989;142:538-541. [http://www.ncbi.nlm.nih.gov:80/entrez/query.fcgi?cmd=Retrieve&db=PubMed&list\\_uids=2746776&dopt=Abstract](http://www.ncbi.nlm.nih.gov:80/entrez/query.fcgi?cmd=Retrieve&db=PubMed&list_uids=2746776&dopt=Abstract)
17. Stephens D. Caecoureterocele and concepts on the embryology and aetiology of ureteroceles. *Aust N Z J Surg* 1971;40:239-248. [http://www.ncbi.nlm.nih.gov:80/entrez/query.fcgi?cmd=Retrieve&db=PubMed&list\\_uids=5279434&dopt=Abstract](http://www.ncbi.nlm.nih.gov:80/entrez/query.fcgi?cmd=Retrieve&db=PubMed&list_uids=5279434&dopt=Abstract)

#### **Ectopic ureter**

1. Carrico C, Lebowitz RL. Incontinence due to an infrasphincteric ectopic ureter: why the delay in diagnosis and what the radiologist can do about it. *Pediatr Radiol* 1998;28:942-949. [http://www.ncbi.nlm.nih.gov:80/entrez/query.fcgi?cmd=Retrieve&db=PubMed&list\\_uids=9880638&dopt=Abstract](http://www.ncbi.nlm.nih.gov:80/entrez/query.fcgi?cmd=Retrieve&db=PubMed&list_uids=9880638&dopt=Abstract)
2. Cendron J, Schulman CC. [Ectopic ureter.] In: *Paediatric urology*. Paris: Flammarion Médecine Sciences, 1985, pp. 147-153. [French]

3. el Ghoneimi A, Miranda J, Truong T, Montfort G. Ectopic ureter with complete ureteric duplication: conservative surgical management. *J Pediatr Surg* 1996;31:467-472.  
[http://www.ncbi.nlm.nih.gov:80/entrez/query.fcgi?cmd=Retrieve&db=PubMed&list\\_uids=8801293&dopt=Abstract](http://www.ncbi.nlm.nih.gov:80/entrez/query.fcgi?cmd=Retrieve&db=PubMed&list_uids=8801293&dopt=Abstract)
4. Komatsu K, Niikura S, Maeda Y, Ishiura Y, Yokoyama O, Namiki M. Single ectopic vaginal ureter diagnosed by computed tomography. *Urol Int* 1999;63:147-150.  
[http://www.ncbi.nlm.nih.gov:80/entrez/query.fcgi?cmd=Retrieve&db=PubMed&list\\_uids=10592508&dopt=Abstract](http://www.ncbi.nlm.nih.gov:80/entrez/query.fcgi?cmd=Retrieve&db=PubMed&list_uids=10592508&dopt=Abstract)
5. Plaire JC, Pope JC 4th, Kropp BP, Adams MC, Keating MA, Rink RC, Casale AJ. Management of ectopic ureters: experience with the upper tract approach. *J Urol* 1997;158:1245-1247.  
[http://www.ncbi.nlm.nih.gov:80/entrez/query.fcgi?cmd=Retrieve&db=PubMed&list\\_uids=9258185&dopt=Abstract](http://www.ncbi.nlm.nih.gov:80/entrez/query.fcgi?cmd=Retrieve&db=PubMed&list_uids=9258185&dopt=Abstract)
6. Robert M, Ennouchi JM, Chevallier P, Guiter J, Averous M. [Diagnosis of ectopic ureteral openings in the seminal tract. Value of modern imaging.] *Progr Urol* 1993;3:1028-1033. [French]  
[http://www.ncbi.nlm.nih.gov:80/entrez/query.fcgi?cmd=Retrieve&db=PubMed&list\\_uids=8305932&dopt=Abstract](http://www.ncbi.nlm.nih.gov:80/entrez/query.fcgi?cmd=Retrieve&db=PubMed&list_uids=8305932&dopt=Abstract)
7. Smith FL, Ritchie EL, Maizels M, Zaontz MR, Hsueh W, Kaplan WE, Firlit CF. Surgery for duplex kidneys with ectopic ureters: ipsilateral ureteroureterectomy versus polar nephrectomy. *J Urol* 1989;142:532-534.  
[http://www.ncbi.nlm.nih.gov:80/entrez/query.fcgi?cmd=Retrieve&db=PubMed&list\\_uids=2746774&dopt=Abstract](http://www.ncbi.nlm.nih.gov:80/entrez/query.fcgi?cmd=Retrieve&db=PubMed&list_uids=2746774&dopt=Abstract)
8. Sumfest JM, Burns MW, Mitchell ME. Pseudoureterocele: potential for misdiagnosis of an ectopic ureter as a ureterocele. *Br J Urol* 1995;75:401-405.  
[http://www.ncbi.nlm.nih.gov:80/entrez/query.fcgi?cmd=Retrieve&db=PubMed&list\\_uids=7735809&dopt=Abstract](http://www.ncbi.nlm.nih.gov:80/entrez/query.fcgi?cmd=Retrieve&db=PubMed&list_uids=7735809&dopt=Abstract)

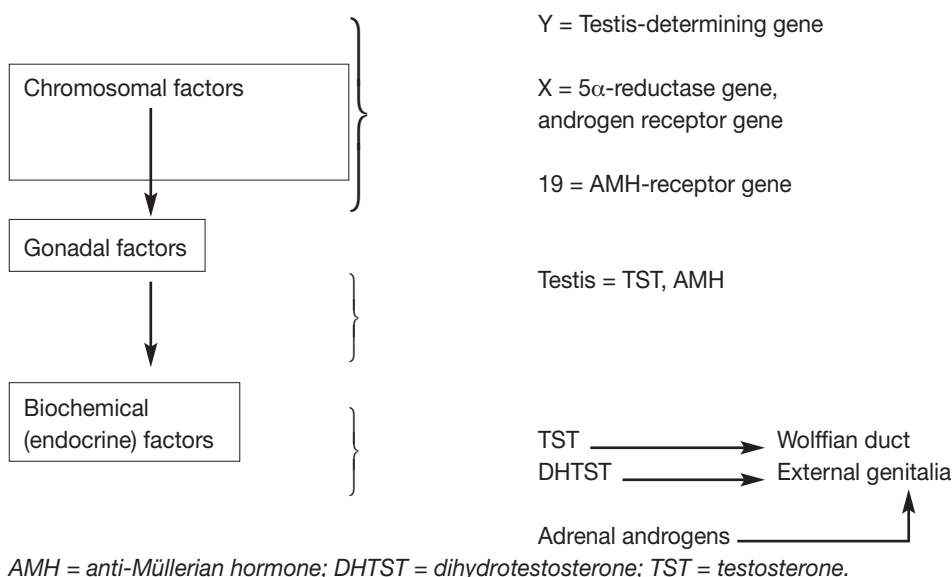
## 16. INTERSEX (ABNORMAL SEXUAL DIFFERENTIATION)

### 16.1 Background

Disorders of sexual differentiation usually manifest themselves by the abnormal appearance of the external genitalia at birth, casting doubt on the baby's gender and causing great anxiety for the baby's family.

The anatomy and physiology of differentiation of the internal and external sexual organs of the fetus is regulated by a variety of factors at three different levels (Figure 4).

**Figure 4. Factors involved in normal sexual differentiation**

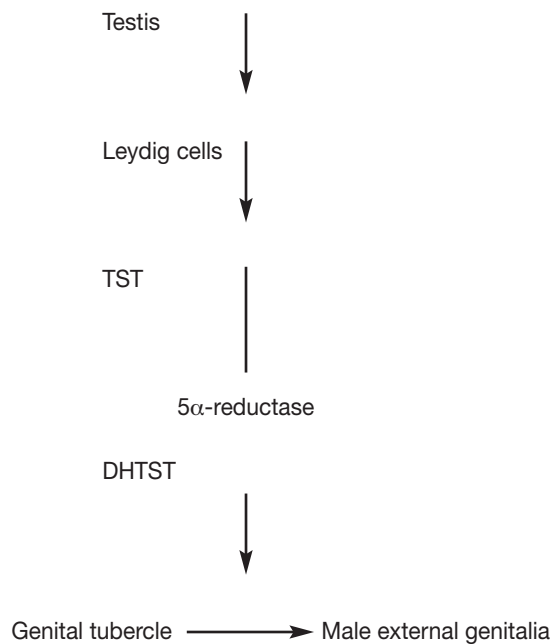


With very few exceptions, a normal 46XX or 46XY karyotype leads to normal sex determination and gonadal differentiation. The presence of the so-called SRY gene (sex-determining region of Y) on the short arm of the Y chromosome leads to differentiation of the fetal gonads into testes. When there is no Y chromosome or SRY gene, the gonad will spontaneously turn into an ovary. However, the absence of one X chromosome (i.e. 45X0) will lead to the early loss of gonadal germ cells and ovarian fibrous degeneration.

The normally functioning fetal testis induces further somatic male differentiation (Figure 5) by means of:

- Anti-Müllerian hormone (AMH). This is secreted by the Sertoli cells and is responsible for Müllerian duct regression; and
- Testosterone (TST) secreted by the Leydig cells. Following its intracellular conversion to dihydrotestosterone (DHTST) by 5 $\alpha$ -reductase, TST is responsible for the maintenance and male differentiation of the Wolffian ducts and virilization of the urogenital sinus and external genitalia (genital tubercle).

**Figure 5. Somatic male differentiation via testicular hormones**



*DHTST = dihydrotestosterone; TST = testosterone.*

Both AMH and DHTST need the presence of their respective cellular receptors in order to exercise their function. Disorders of AMH or TST (DHTST) biosynthesis or action may lead to intersex states (Table 3). The fact that the androgen-receptor gene lies on the X chromosome explains the virilization of the female fetus in adrenogenital syndrome (AGS).

**Table 3: Effects of inadequate biosynthesis or action of AMH, TST or DHTST**

AMH ↓	Retention of Müllerian structures
TST ↓	Inadequate differentiation of Wolffian duct structures (i.e. epididymis, vas deferens, seminal vesicles)
DHTST ↓	Inadequate differentiation of genital tubercle, resulting in inadequate masculinization of external genitalia (severe hypospadias, microphallus)

*AMH = anti-Müllerian hormone; DHTST = dihydrotestosterone; TST = testosterone.*

## 16.2 Classification

The classification proposed by Allen in 1976 (based on gonadal histology with subclassifications made primarily by aetiology) has the advantage that gonadal histology is easier to interpret than karyotype or morphology of the external genitalia (Table 4).

**Table 6: Classification of intersex states (adapted from Allen 1976). Major categories are grouped by gonadal histology, with subclassification by aetiology**

**I. Ovary only: Female pseudohermaphrodite (karyotype 46XX)**

A. Secondary to endogenous androgens (CAH)

- 21-hydroxylase deficiency
- 11 $\beta$ -hydroxylase deficiency
- 3 $\beta$ -hydroxysteroid dehydrogenase deficiency

B. Secondary to maternal androgens (exogenous ingestion – endogenous production)

**II. Testis only: Male pseudohermaphrodite (karyotype 46XY)**

A. Secondary to inadequate androgen (TST) production

- 20 $\alpha$ -hydroxylase deficiency
- 3- $\beta$ -hydroxysteroid dehydrogenase deficiency
- 17 $\beta$ -hydroxylase deficiency
- 17,20-desmolase deficiency
- 17-ketosteroid reductase deficiency

B. Secondary to inadequate conversion of TST to DHTST

- 5 $\alpha$ -reductase deficiency

C. Secondary to inadequate androgen (TST/DHTST) utilization: androgen receptor deficiency

- Incomplete
- Complete (testicular feminization)

D. Secondary to deficient AMH

- Hernia uteri inguinalis

**III. Testis plus ovary: True hermaphrodite (karyotype 46XY, 46XX, mosaic)**

**IV. Testis plus streak gonad: Mixed gonadal dysgenesis (karyotype most often 45XO/46XY)**

**V. Streak gonad plus streak gonad: Pure gonadal dysgenesis (karyotype 45XO [Turner's syndrome], 46XX, 46XY)**

**VI. Miscellaneous**

- Dysgenetic testes
- Teratogenic factors

AMH = anti-Müllerian hormone; CAH = congenital adrenal hyperplasia; DHTST = dihydrotestosterone; TST = testosterone.

Recent consensus is to name these entities on the basis of karyotype and degree of virilization. The synonyms are given in parentheses.

*16.2.1 Ovary only (female pseudohermaphrodite)*

*[Disorder of sexual development and differentiation in a 46 XX patient - virilized female]*

These are 46XX patients with normal ovaries and uterus, but virilized external genitalia due to the endogenous overproduction of androgens by the fetal adrenal glands (congenital adrenal hyperplasia [CAH], AGS). These patients account for approximately two-thirds of intersex states seen in clinical practice.

*16.2.2 Testis only (male pseudohermaphrodite)*

*[Disorder of sexual development and differentiation in a 46 XY patient - under-virilized male]*

These are 46XY patients with inadequate virilization of the external genitalia due to deficient biosynthesis of TST, inadequate conversion of TST to DHTST (lack of 5 $\alpha$ -reductase), or inadequate TST/DHTST utilization (lack of androgen receptors). They also include patients with AMH deficiency, who have adequate male external genitalia and retained Müllerian structures, i.e. tubes and uterus contained in a hernia (hernia uteri inguinalis).



### 16.2.3 Testis plus ovary (true hermaphrodite)

[Disorder of sexual development and differentiation with a variation of combined gonadal histology of ovarian and testicular tissue]

Patients have both testicular tissue and ovarian tissue resulting from sex chromosome mosaicism, chimerism or Y chromosome translocation. Their karyotype varies, i.e. 46XX, 46XY or mosaic 46XX/46XY. In most cases, external genitalia are ambiguous but masculinized to variable degrees, and 75% are raised as male.

### 16.2.4 Testis plus streak gonad (mixed gonadal dysgenesis)

This is the second most common category of intersexuality. The most common karyotype is 45XO/46XY mosaicism. The existing testis is infertile and Müllerian structures may be present on both sides. There is a high risk of gonadoblastoma of the existing testis after puberty.

### 16.2.5 Streak gonad plus streak gonad (pure gonadal dysgenesis)

Phenotypic females with bilateral gonadal streaks with three subgroups of karyotypes: 45XO (Turner's syndrome), 46XX and 46XY. The latter subgroup is particularly prone to malignant degeneration of the streak gonads.

**Table 5: Findings in a newborn suggesting the possibility of intersexuality (adapted from the American Academy of Pediatrics)**

- **Apparent male**
- Severe hypospadias associated with bifid scrotum
- Undescended testis (-es) with hypospadias
- Bilateral non-palpable testes in a full-term apparently male infant
- **Apparent female**
- Clitoral hypertrophy of any degree, non-palpable gonads
- Vulva with single opening
- **Indeterminate**
- Ambiguous genitalia

## 16.3 Diagnosis

### 16.3.1 The neonatal emergency

The first step is to recognize the possibility of intersexuality (Table 5) and to refer the newborn baby immediately to a tertiary paediatric centre fully equipped with neonatal, genetics, endocrinology and urology units. At the centre, the situation should be explained to the parents fully and kindly. Registering and naming the newborn should be delayed as long as necessary. A careful family history must be taken followed by a thorough clinical examination (Table 6).

**Table 6: Diagnostic work-up of neonates with ambiguous genitalia**

#### History (family, maternal, neonatal)

- Parental consanguinity
- Previous intersex disorders or genital anomalies
- Previous neonatal deaths
- Primary amenorrhoea or infertility in other family members
- Maternal exposure to androgens
- Failure to thrive, vomiting, diarrhoea of the neonate

#### Physical examination

- Pigmentation of genital and areolar area
- Hypospadias or urogenital sinus
- Size of phallus
- Palpable and/or symmetrical gonads
- Blood pressure

#### Investigations

- Blood analysis: 17-hydroxyprogesterone, electrolytes, LH, FSH, TST, cortisol, ACTH
- Urine: adrenal steroids

- Karyotype
- Ultrasound
- Genitogram
- hCG stimulation test
- Androgen-binding studies
- Endoscopy

*ACTH = adrenocorticotrophic hormone; FSH = follicle stimulating hormone; hCG = human chorionic gonadotrophin; LH = luteinizing hormone; TST = testosterone.*

### 16.3.2 Palpable gonad

It must be remembered that if it is possible to feel a gonad, it is almost certainly a testis; this clinical finding therefore virtually excludes female pseudohermaphrodites (i.e. CAH).

### 16.3.3 Laboratory investigations

The following laboratory investigations are mandatory:

- karyotype
- plasma 17-hydroxyprogesterone assay
- plasma electrolytes
- ultrasonography to evaluate the presence of Müllerian duct structures.

These investigations will give evidence of CAH, which is the most frequent intersex disorder. If this evidence is found, no further investigation is needed. Otherwise, the laboratory work-up should proceed further.

The hCG stimulation test is particularly helpful in differentiating the main syndromes of male pseudohermaphrodites by evaluating Leydig cell potential. Testosterone metabolism is evaluated and the presence or absence of metabolites helps to define the problem. An extended stimulation can help to define phallic growth potential and to induce testicular descent in some cases of associated cryptorchidism.

The results are interpreted as follows:

- normal increase in both TST and DHTST = androgen insensitivity syndrome.
- subnormal increase in both TST and DHTST with increasing androgen precursors = TST biosynthetic block.
- normal increase in TST, but subnormal increase in DHTST = 5 $\alpha$ -reductase deficiency.

### 16.3.4 Making a diagnosis

The following rules of thumb can be applied regarding a precise diagnosis.

Absence of a Y-chromosome and no palpable gonads are found in CAH or a female pseudohermaphrodite due to maternal exposure to androgens. In the case of CAH, immediate medical therapy must be instituted (corticosteroid substitution, electrolyte and blood pressure monitoring).

The presence of a Y-chromosome with one or two palpable gonads (usually inguinal) indicates the following:

- If there are Müllerian duct structures, the anomaly concerns gonadal dysgenesis or true hermaphroditism.
- If there are no Müllerian duct structures, the anomaly concerns a male hermaphrodite, due either to abnormal TST biosynthesis, inadequate conversion of TST to DHTST (5 $\alpha$ -reductase deficiency) or receptor anomaly (androgen insensitivity syndrome).

### 16.3.5 Gender assignment

This is a very complicated task and it should take place after a definitive diagnosis has been made. The idea that an individual is sex-neutral at birth and that rearing determines gender development is no longer the standard. Gender assignment decision should be based upon:

- age at presentation
- fertility potential (if attainable at all)
- size of the penis (good sexual function)
- presence of a functional vagina (good sexual function)
- endocrine function
- malignancy potential
- antenatal testosterone exposure
- general appearance
- psychosocial well-being and a stable gender identity.

### 16.3.6 Late diagnosis and management

Problems arise when patients with disordered sexual differentiation are brought for urological consultation during late childhood or adolescence. These individuals fail to conform to their sex of rearing, cannot perform sexually or still have gonads with neoplastic potential.

Female patients with CAH may complain of difficulties during intercourse because of a narrow introitus and inadequate vaginal opening. The patient should be carefully examined, if necessary under general anaesthesia, and a gynaecologist should be called in to assess the need for (revision) vaginoplasty.

Male patients with CAH may present with signs of excess androgen production such as rapid growth, hirsutism and precocious puberty. Steroid treatment will stall their precocious puberty and prevent premature closure of the epiphyses.

Male pseudohermaphrodites due to  $5\alpha$ -reductase deficiency, who have been reared as girls, will develop the secondary characteristics dependent on TST at puberty. They become aggressively male in behaviour, the 'clitoris' grows, the voice breaks, and the body habitus becomes obviously male, but there is no acne or facial hirsutism. Careful urological examination will reveal high-lying testes. The question of gender re-assignment at this stage may become the subject of prolonged discussion. Re-evaluation of the child by a team of specialists, including a psychiatrist, is mandatory.

## 16.4 Treatment

Problems of ambiguous genitalia should, in principle, be managed by a team of specialists in order to reach a prompt and correct diagnosis. Amongst this group, urologists should have an important role. Urologists should work in close co-operation with neonatologists, endocrinologists, geneticists and psychiatrist in order to achieve the best possible management and outcome for these patients.

### 16.4.1 Genitoplasty

*Masculinizing genitoplasty* incorporates the following stages.

- hormone therapy early in life is advocated by many doctors. The level of evidence that restoration of normal penile size can be obtained is low
- excision of Müllerian duct structures. This is necessary, firstly, because subsequent urethroplasty may cause urine retention and infection within an existing pseudocolpos, and secondly, because casual discovery of a retained Müllerian structure later in life may raise questions about the patient's gender
- urethroplasty with release of chordee and correction of scrotal deformities
- orchidopexy of testes that are to be retained.

*Feminizing genitoplasty* in CAH should be performed once the patient's general status, blood pressure and electrolyte balance have been stabilized by systemic steroid substitution. This is usually achieved around the second or third month of life. The family should be cautioned, however, that re-evaluation of the vaginal opening and (revision) vaginoplasty may be needed at puberty.

### 16.4.2 Indications for the removal of gonads

The gonads of intersex patients should be removed in the following cases.

*Inappropriate gonadal type for the sex of rearing.* Gonads should be removed in male pseudohermaphrodites, who are to be reared as girls, or true hermaphrodites, where discordant gonadal tissue is not needed.

*High risk of malignancy (gonadoblastoma/dysgerminoma).* A high risk of malignancy is particularly true for patients with mixed gonadal dysgenesis and those with true gonadal dysgenesis and 46XY karyotype. The risk is less for male pseudohermaphrodites with androgen receptor insensitivity and true hermaphrodites with 46XY karyotype. As gonadal tumour does not develop until after puberty, gonadal removal can be postponed until puberty.

## 16.5 REFERENCES

1. Allen TD. Disorders of sexual differentiation. *Urology* 1976;7(4 Suppl):1-32.  
[http://www.ncbi.nlm.nih.gov/entrez/query.fcgi?cmd=Retrieve&db=pubmed&dopt=Abstract&list\\_uids=772919&query\\_hl=76&itool=pubmed\\_docsum](http://www.ncbi.nlm.nih.gov/entrez/query.fcgi?cmd=Retrieve&db=pubmed&dopt=Abstract&list_uids=772919&query_hl=76&itool=pubmed_docsum)
2. Evaluation of the newborn with developmental anomalies of the external genitalia. *American Academy of Pediatrics. Committee on Genetics Pediatrics* 2000;106:138-142.  
[http://www.ncbi.nlm.nih.gov/entrez/query.fcgi?cmd=Retrieve&db=pubmed&dopt=Abstract&list\\_uids=10878165&query\\_hl=80&itool=pubmed\\_DocSum](http://www.ncbi.nlm.nih.gov/entrez/query.fcgi?cmd=Retrieve&db=pubmed&dopt=Abstract&list_uids=10878165&query_hl=80&itool=pubmed_DocSum)

3. Androulakakis PA. *Pediatric urology*. Athens: Beta Publishing Co, 1993.
4. Creighton SM, Minto CL, Steele SJ. Objective cosmetic and anatomical outcomes at adolescence of feminising surgery for ambiguous genitalia done in childhood. *Lancet* 2001;358:124-125.  
[http://www.ncbi.nlm.nih.gov/entrez/query.fcgi?cmd=Retrieve&db=pubmed&dopt=Abstract&list\\_uids=11463417&query\\_hl=85&itool=pubmed\\_docsum](http://www.ncbi.nlm.nih.gov/entrez/query.fcgi?cmd=Retrieve&db=pubmed&dopt=Abstract&list_uids=11463417&query_hl=85&itool=pubmed_docsum)
5. Diamond M, Sigmundson HK. Management of intersexuality. Guidelines for dealing with persons with ambiguous genitalia. *Arch Pediatr Adolesc Med* 1997;151:1046-1050.  
[http://www.ncbi.nlm.nih.gov/entrez/query.fcgi?cmd=Retrieve&db=pubmed&dopt=Abstract&list\\_uids=9343018&query\\_hl=87&itool=pubmed\\_docsum](http://www.ncbi.nlm.nih.gov/entrez/query.fcgi?cmd=Retrieve&db=pubmed&dopt=Abstract&list_uids=9343018&query_hl=87&itool=pubmed_docsum)
6. Fekete CN, Lortat-Jacob S. *Management of the intersex child at birth*. Proceedings of Pediatric Uroendocrinology, ESPU Annual Course, Paris: 1996.
7. Fekete CN. Surgical management of the intersex patient: an overview in 2003. *J Ped Surg* 2004;39:144-145.
8. Imperato-McGinley J, Peterson RE, Gautier T, Sturla E. Male pseudohermaphroditism secondary to 5 alpha-reductase deficiency - a model for the role of androgens in both the development of the male phenotype and the evolution of a male gender identity. *J Steroid Biochem* 1979;11:637-645.  
[http://www.ncbi.nlm.nih.gov/entrez/query.fcgi?cmd=Retrieve&db=pubmed&dopt=Abstract&list\\_uids=491628&query\\_hl=99&itool=pubmed\\_docsum](http://www.ncbi.nlm.nih.gov/entrez/query.fcgi?cmd=Retrieve&db=pubmed&dopt=Abstract&list_uids=491628&query_hl=99&itool=pubmed_docsum)
9. Manuel M, Katayama PK, Jones HW Jr. The age of occurrence of gonadal tumors in intersex patients with a Y chromosome. *Am J Obstet Gynecol* 1976;124:293-300.  
[http://www.ncbi.nlm.nih.gov/entrez/query.fcgi?cmd=Retrieve&db=pubmed&dopt=Abstract&list\\_uids=1247071&query\\_hl=101&itool=pubmed\\_docsum](http://www.ncbi.nlm.nih.gov/entrez/query.fcgi?cmd=Retrieve&db=pubmed&dopt=Abstract&list_uids=1247071&query_hl=101&itool=pubmed_docsum)
10. Reiner WG. Sex assignment in the neonate with intersex or inadequate genitalia. *Arch Pediatr Adolesc Med* 1997;151:1044-1045.  
[http://www.ncbi.nlm.nih.gov/entrez/query.fcgi?cmd=Retrieve&db=pubmed&dopt=Abstract&list\\_uids=9343017&query\\_hl=103&itool=pubmed\\_docsum](http://www.ncbi.nlm.nih.gov/entrez/query.fcgi?cmd=Retrieve&db=pubmed&dopt=Abstract&list_uids=9343017&query_hl=103&itool=pubmed_docsum)
11. Rubin RT, Reinisch JM, Haskett RF. Postnatal gonadal steroid effects on human behavior. *Science* 1981;211:1318-1324.  
[http://www.ncbi.nlm.nih.gov/entrez/query.fcgi?cmd=Retrieve&db=pubmed&dopt=Abstract&list\\_uids=7209511&query\\_hl=105&itool=pubmed\\_docsum](http://www.ncbi.nlm.nih.gov/entrez/query.fcgi?cmd=Retrieve&db=pubmed&dopt=Abstract&list_uids=7209511&query_hl=105&itool=pubmed_docsum)
12. Savage MO, Lowe DG. Gonadal neoplasia and abnormal sexual differentiation. *Clin Endocrinol* 1990;32:519-533.  
[http://www.ncbi.nlm.nih.gov/entrez/query.fcgi?cmd=Retrieve&db=pubmed&dopt=Abstract&list\\_uids=2189603&query\\_hl=107&itool=pubmed\\_docsum](http://www.ncbi.nlm.nih.gov/entrez/query.fcgi?cmd=Retrieve&db=pubmed&dopt=Abstract&list_uids=2189603&query_hl=107&itool=pubmed_docsum)
13. Sohval AR. 'Mixed' gonadal dysgenesis: a variety of hermaphroditism. *Am J Hum Genet* 1963;15:155-158.  
[http://www.ncbi.nlm.nih.gov/entrez/query.fcgi?cmd=Retrieve&db=pubmed&dopt=Abstract&list\\_uids=13989874&query\\_hl=109&itool=pubmed\\_docsum](http://www.ncbi.nlm.nih.gov/entrez/query.fcgi?cmd=Retrieve&db=pubmed&dopt=Abstract&list_uids=13989874&query_hl=109&itool=pubmed_docsum)
14. Whitaker RH, Williams DM. Diagnostic assessment of children with ambiguous genitalia. *Eur Urol Update Series* 1993;2:2-7.

### Chairman's note:

The aim of this paper is to outline a practical and preliminary approach for general practitioners. Due to the complexity and rarity of this condition, patients should be referred to designated centres where a multidisciplinary approach is possible.

The management of intersex problems in children is highly controversial. Sex assignment of children with ambiguous genitalia remains a difficult decision for the families involved and is subject to controversial discussion among professionals and self-help groups. The current approach to management argues against the need for, and appropriateness of, an early decision made by parents and physicians. Delayed management requires a complete disclosure of information regarding the child's condition and the deferral of all surgery until at least adolescence. A report of the recently held consensus meeting on intersex management is pending and we anticipate including data from the report in our next version of guidelines.

One of our group members Professor Phillip Androulakakis passed away just before the completion of this document. We should like to acknowledge his special expertise and input in this guideline, in particular his contribution to the field of abnormal sexual differentiation. He will be greatly missed.

## 17. ABBREVIATIONS USED IN THE TEXT

*This list is not comprehensive for the most common abbreviations*

AGS	adrenogenital syndrome
ACTH	adrenocorticotrophic hormone
AMH	anti-Müllerian hormone
ARM	anorectal malformation
CAH	congenital adrenal hyperplasia
CIC	clean self-intermittent catheterization
CNS	central nervous system
CRP	C-reactive protein
DDAVP	desmopressine
CT	computed tomography
DHTST	dihydrotestosterone
DMSA	dimercaptosuccinic acid
EMG	electromyography
ESR	erythrocyte sedimentation rate
ESWL	extracorporeal shockwave lithotripsy
FSH	follicle stimulating hormone
GnRH	gonadotrophin-releasing hormone
hCG	human chorionic gonadotrophin
ICCS	International Children's Continence Society
IVU	intravenous urogram
LH	luteinizing hormone
LHRH	luteinizing hormone releasing hormone
LUT(S)	lower urinary tract (symptoms)
MRI	magnetic resonance imaging
PNL	percutaneous litholapaxy
RCT	randomized controlled treatment trials
RN	reflux nephropathy
RNC	radionuclide cystography
RTA	renal tubular acidosis
Tc-MAG3 (99m)	technetium-99m mercaptoacetyltriglycine (MAG3)
TIP	tubularized incised urethral plate
TST	testosterone
UPJ	ureteropelvic junction
URS	ureterorenoscopy
US	ultrasound
UTIs	urinary tract infections
VCUG	voiding cystourethrography
VRR	vesicorenal reflux
VUR	vesicoureteral reflux
VUS	voiding urosonography